Facultad de Odontología

Odontoestomatología
DOI: 10.22592/ode2026n47e249

Surgical treatment of intraosseous defects combined with soft tissue enhancement using connective tissue graft

A scoping review

INVESTIGATION

Tratamiento quirúrgico de defectos intraóseos en conjunto con mejora de tejido blando utilizando injerto de tejido conectivo

Una revisión sistemática exploratoria

Tratamento cirúrgico de defeitos intraósseos combinado com melhoria do tecido mole utilizando enxerto de tecido conjuntivo

Uma revisão de escopo

Abstract

This study evaluated the clinical and radiographic outcomes of surgical treatment for intrabony defects and gingival recessions using connective tissue grafts. A scoping review was conducted following PRISMA-ScR guidelines, searching PubMed, SCOPUS, and SciELO databases. Clinical trials, cohort studies, and case reports reporting outcomes such as probing depth, clinical attachment level, gingival recession coverage, and keratinized tissue characteristics were included. Nine studies with follow-up periods ranging from 6 to 36 months met the inclusion criteria. The findings showed an average probing depth reduction of 4.73 mm and a clinical attachment gain of 4.63 mm. Gingival recession coverage demonstrated favorable outcomes, including complete coverage in several cases, with increases in apico-coronal height and keratinized tissue thickness of up to 3 mm. Radiographically, stable bone fill was observed in all cases, accompanied by increased radiopacity and preservation of interproximal bone support. The use of connective tissue grafts, in combination with enamel matrix derivatives and/or bone grafts, enhanced clinical parameters and resulted in radiographically visible bone regeneration, while also improving soft tissue characteristics, with the potential to strengthen prognosis and patient comfort for treated teeth.

AUTHORS

Bernardita Cattarinich-Araya[1]
Camila Serrano Spalinger[1]
Enzo Niccoli-Merello[1]
Jaime Segovia-Chamorro[1]

CORRESPONDENCE:
Jaime Segovia-Chamorro
jaime.segovia@uv.cl

Received: April 29, 2025
Accepted: July 25, 2025

CC BY

Keywords
Intraosseous defects, connective tissue graft, periodontal regeneration, gingival recession, bilaminar technique.

[1] Cátedra de Periodoncia, Escuela de Odontología, Facultad de Odontología, Universidad de Valparaíso, Chile.

Resumen

Este estudio evaluó los resultados clínicos y radiográficos del tratamiento quirúrgico de defectos intraóseos que utilizaron injertos de tejido conectivo. Se realizó una revisión sistemática exploratoria orientada por las guías PRISMA-ScR, que buscó en bases de datos como PubMed, SCOPUS y SciELO. Se consideró ensayos clínicos, estudios de cohorte y reportes de caso que proporcionaran resultados clínicos y radiográficos como profundidad de sondaje, nivel de inserción clínica, cobertura de recesiones gingivales y características del tejido queratinizado. Se incluyó nueve estudios con seguimientos de 6 hasta 36 meses. Los resultados muestran una reducción promedio de la profundidad de sondaje de 4,73 mm y una ganancia en el nivel de inserción clínica de 4,63 mm. La cobertura de recesiones gingivales asociadas muestra resultados favorables, incluso cobertura total en varios casos, junto con un aumento en la altura apico-coronal y grosor del tejido queratinizado de hasta 3 mm. Radiográficamente, se evidenció un relleno óseo estable en todos los casos, acompañado de mayor radiopacidad y preservación del soporte óseo interproximal. El uso de injerto de tejido conectivo junto con derivados de la matriz de esmalte y/o injertos óseos, mejora los parámetros clínicos y produce un relleno óseo radiográficamente visible, además, proporciona resultados adicional en las características de los tejidos blandos, con la potencialidad de mejorar el pronóstico y la comodidad para los dientes tratados.

Palabras clave

Defectos intraóseos, injerto de tejido conectivo, regeneración periodontal, recesión gingival, técnica bilaminar.

Resumo

Este estudo avaliou os resultados clínicos e radiográficos do tratamento cirúrgico de defeitos intraósseos e recessões gengivais usando enxertos de tecido conjuntivo. Foi realizada uma revisão sistemática exploratória seguindo as diretrizes PRISMA-ScR, pesquisando em bases de dados como PubMed, SCOPUS e SciELO. Foram considerados ensaios clínicos, estudos de coorte e relatos de casos que forneceram resultados clínicos e radiográficos, como profundidade de sondagem, nível de inserção clínica, cobertura de recessões gengivais e características do tecido queratinizado. Foram incluídos nove estudos com acompanhamento de seis a trinta e seis meses. Os resultados mostram uma redução média na profundidade de sondagem de 4,73 mm e um ganho no nível de inserção clínica de 4,63 mm. A cobertura das recessões gengivais associadas apresentou resultados favoráveis, incluindo cobertura total em vários casos, juntamente com um aumento na altura apico-coronal e na espessura do tecido queratinizado de até 3 mm. Radiograficamente, observou-se preenchimento ósseo estável em todos os casos, acompanhado de maior radiopacidade e preservação do suporte ósseo interproximal. O uso de enxertos de tecido conjuntivo juntamente com derivados da matriz do esmalte e/ou enxertos ósseos melhora os parâmetros clínicos e no preenchimento ósseo radiograficamente visível, além de proporcionar melhora adicional nas características do tecido mole, com potencial para melhorar o prognóstico e o conforto dos dentes tratados.

Palavras-chave

Defeitos intraóseos, enxerto de tecido conjuntivo, regeneração periodontal, recessão gengival, técnica bilaminar.

Introduction and background

Over the last forty years, surgical treatment of intraosseous defects has evolved significantly—from traditional techniques such as access flaps or open flap debridement, bone grafting, and guided tissue regeneration to modern approaches that include combined therapies, the use of various biologic agents, and minimally invasive surgery.[1] These more recent techniques, developed since the 1990s, have shown superior results compared to access flap surgery[2,3], even without the use of biomaterials[4,5]. Consequently, today this technique is recommended as the treatment of choice for intraosseous defects.[6,7]

Currently, treatment guidelines and systematic reviews support the effectiveness of these interventions in several clinical parameters, such as pocket closure, clinical attachment gain, probing depth reduction, and even their sustained beneficial effects over time and on tooth retention.[1,2,3,4,5,7] However, the literature has not ful-

ly addressed the potential soft tissue sequelae that may arise after treatment: loss of interproximal tissue, gingival recession, and reduction of the apico-coronal band of keratinized tissue, which may compromise both the esthetics and functionality of periodontal tissues.[8]

For this reason, some authors have proposed combining different approaches for the regenerative/reconstructive treatment of intraosseous defects with periodontal plastic surgery techniques,[6] not only to treat these lesions but also to improve soft tissue characteristics through the complementary use of coronally advanced flaps (CAF) and connective tissue grafts (CTG).(**Figure 1**) These interventions have the potential to provide mechanical stability to the blood clot and prevent soft tissue collapse,[6] with the possibility of achieving improved soft tissue quality after regenerative therapy, a better treatment prognosis, and at the same time greater comfort and patient satisfaction.[8]

This study aims to evaluate the clinical and radiographic outcomes of surgical treatment of intraosseous defects using techniques incorporating connective tissue grafts, with emphasis on their impact on both soft and hard tissues through a scoping review.

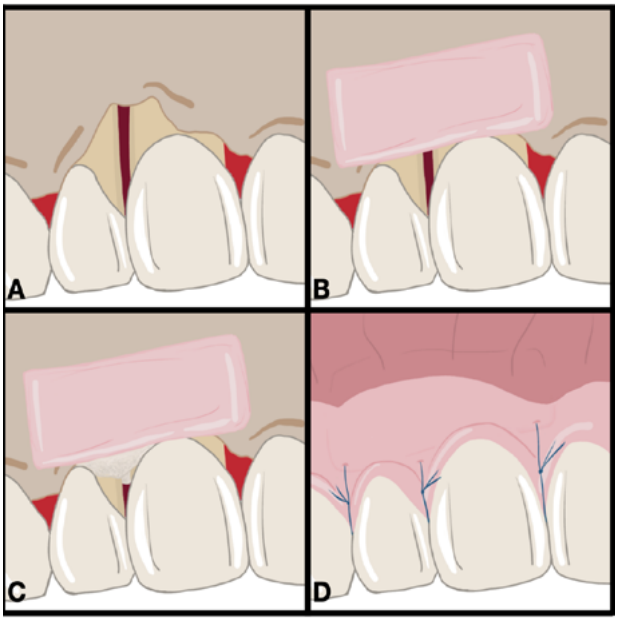

Figure 1. Illustrative diagram of the connective tissue wall technique for intraosseous defects: A: Initial situation showing the bone defect in the affected region. B: Fixation of the connective tissue graft to the buccal wall, adapted to the intraosseous defect. C: Placement of the bone graft material into the defect. D: Flap closure, usually coronally advanced, with sutures. Own authorship.

Materials and methods

This work consisted of an exploratory systematic review following the PRISMA-ScR[10] guidelines, without protocol registration in any database. It was guided by a research question structured according to PCC (Patients, Concept, and Context): "In patients with periodontitis and intraosseous defects, what are the outcomes of surgical treatment of intraosseous defects using connective tissue grafts in the context of secondary management of the disease?" Records such as randomized clinical trials, controlled clinical trials, case series, cohort studies, and case reports conducted in humans diagnosed with intraosseous defects were included. A minimum postoperative follow-up of six months was required, with specification of clinical, radiographic, or both types of outcomes after surgical treatment. In addition, records had to include systemically healthy, non-smoking patients and be published in English or Spanish. Conversely, animal studies, systematic or narrative reviews, and those that did not provide a detailed surgical protocol or did not report clinical parameters were excluded.

Search strategy

Three databases were used to collect studies: PubMed/Medline, SCOPUS, and SciELO. The search was conducted in September 2024 independently by two investigators (BC and CS). It was restricted to articles published within the last ten years, including clinical trials, case reports, case series, and cohort studies. To ensure the relevance of the results, a manual filter was applied in each database, and a manual search was also performed to ensure that the greatest amount of available evidence was considered, reducing the risk of omission in the data collection process.

The electronic search in the PubMed/Medline database was conducted using a combination of MeSH terms and free terms: ((“Intrabony defect”) OR (“Infrabony defect”) OR (“Intraosseous”)) AND ((“Connective tissue graft”) OR (“Wall technique”) OR (“Connective tissue wall”)) NOT (“Suprabony”) NOT (“Dental implants” [MeSH Terms]) NOT (“Peri-implantitis/Surgery” [MeSH Terms]) NOT (“Furcation defects” [MeSH Terms]).

The SCOPUS database search strategy relied on a combination of free terms, aiming to optimize both precision and comprehensiveness. This approach complemented the initial search with additional relevant studies. The terms used were: (ALL(“wall technique”) OR ALL(“intra bony defects”) OR ALL(“infra bony defects”) OR ALL(“non contained defects”) AND ALL(“connective tissue graft”) AND ALL(“soft tissue”) OR ALL(“gingival

recession") AND NOT ALL("supra bone") AND NOT ALL("furcation defects") AND NOT ALL(implants) AND NOT ALL("orthodontic treatment")), with the subject filter "Dentistry" applied.

In the SciELO search, a combination of free terms was used: (Intrabony defect) OR (Infrabony defect) OR (Connective tissue graft) OR (Wall technique dentistry) AND NOT (Suprabony) AND NOT (Dental implants) AND NOT (Peri-implantitis) AND NOT (Furcation defects). The WoS subject filter "Dentistry" was also applied.

Study selection

A total of 51 records were initially identified. After applying the inclusion criteria and reviewing titles and abstracts in Rayyan, duplicate and unrelated records were excluded. Additionally, five more records were incorporated through a manual search. Full-text review was then performed, and one record was excluded for not employing CTG in the surgical technique, resulting in nine records selected for data extraction and analysis (**Figure 2**). Any doubts or discrepancies were resolved by consultation with a third investigator (JS).

For data extraction, the following aspects were considered: author, title, and year of publication; study design; study population; study group; follow-up time; parameters measured; keywords; and main findings. In addition, outcomes related to variations in clinical parameters before and after the procedure were evaluated, including probing depth (PS), clinical attachment level (CAL), gingival recession (GR), distance of the papilla from the contact point or tip of the papilla (TP), and, radiographically, intraosseous defect fill (IDF).

The critical appraisal of each study's quality was carried out independently by two reviewers (BC, CS) following the Joanna Briggs Institute (JBI) guidelines according to study type,[11] to be subsequently reconciled.

Results

This review included nine records: seven case reports[12–16,18,19], one retrospective cohort study[20], and one case series[17]. The general characteristics of the selected studies are shown in **Table 1**.

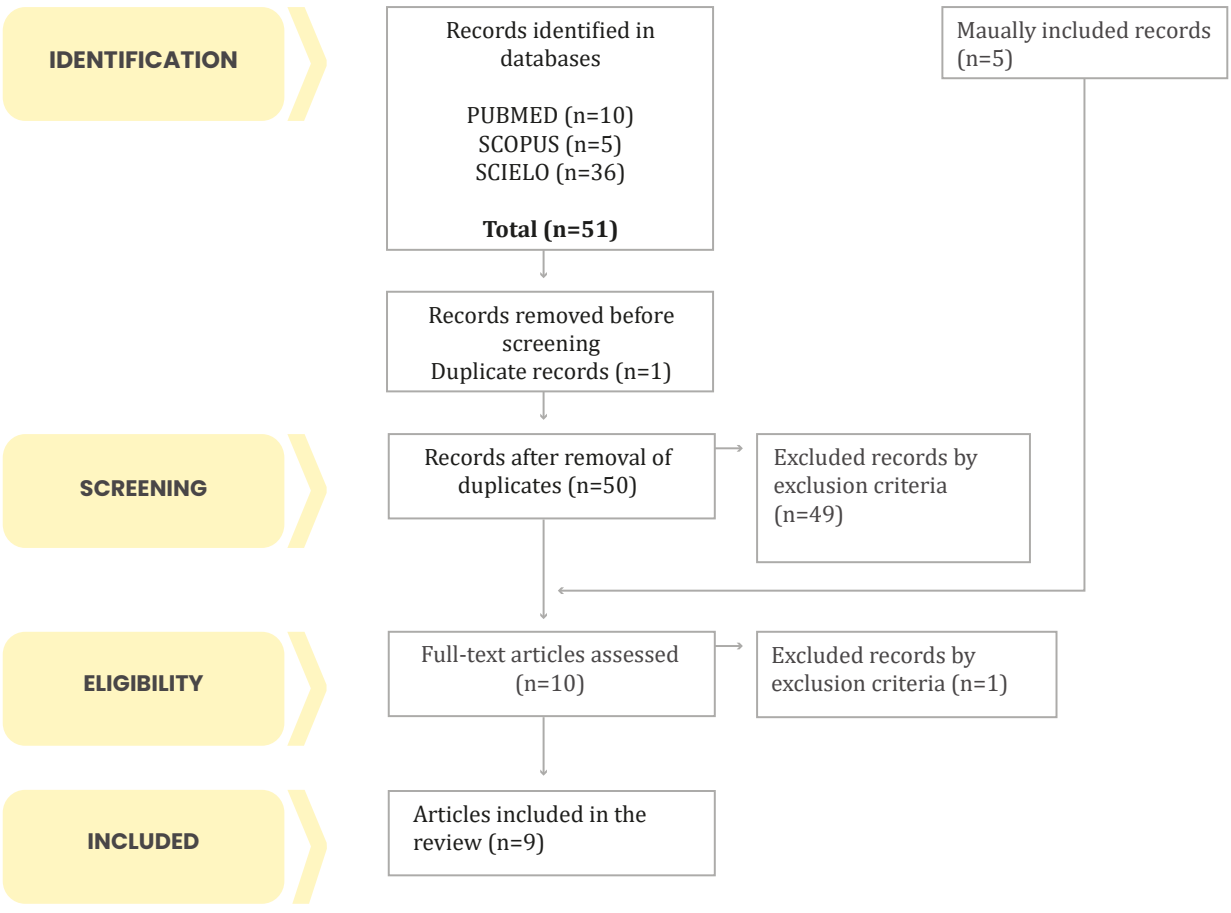

Figure 2. Prisma Flowchart

Tabla 1

Authors	Design	Study Population	Treatment	Follow-up Time	Clinical and Radiographic Outcomes
Zuchelli et. al 2014[18]	Case reports	2 systemically healthy patients, 37 and 42 years old, presenting intraosseous defects and recessions.	Surgical technique CAF + CTG + EMD	12 months	PD, CAL, GR, RC, TP-D, IDF, and radiopacity
Trombelli et. al. 2016[20]	Retrospective cohort	30 patients with intraosseous defects.	Surgical technique SFA + EMD and DBBM (15 patients) / Surgical technique SFA + CTG + EMD and DBBM (15 patients)	6 months	PD, CAL, GR, IDF, KTG (SFA + CTG)
Santoro et. al. 2016[12]	Case reports	2 patients with intraosseous defects associated with gingival recessions RT3 or Miller Class IV with Class II papilla defect. Systemically healthy patients.	**Case 1:** Surgical technique CAF + CTG + EMD + xenograft. **Case 2:** Surgical technique CAF without vertical releasing incisions + CTG + EMD + xenograft.	24 months	PD, CAL, GR, IDF, KTG, KTH, TP-D
Zucchelli et. al. 2016[12]	Case report	Male patient, lingual piercing user for 5 years, with lingual gingival recessions in both mandibular central incisors associated with an intraosseous defect. Systemically healthy.	Surgical technique CAF + CTG + EMD	6 months	PD, CAL, GR, RC, IDF, KTG, KTH
Zuchelli et. al. 2017[19]	Case reports	2 patients with intraosseous defects associated with gingival recession in maxillary anterior teeth. Systemically healthy patients.	Case 1 and 2: Papilla preservation flap + CTG + EMD	24 and 36 months	PD, CAL, GR, IDF, TP-D
Moreno et. al. 2019[16]	Case report	4 patients with non-contained intraosseous defects in maxillary incisors.	Surgical technique NIPSA + CTG + EMD + xenograft	12 months	PD, CAL, GR, IDF, BoP, TP-D
Bravard et. al. 2022[17]	Case series	12 patients, Age: 53.4 ± 9.6 years, non-smokers, systemically healthy.	Surgical technique CAF + CTG + EMD + xenograft	12 months	PD, CAL, GR, IDF, TP-D
Mourlaas et. al. 2022[14]	Case report	3 patients, 18 years old, systemically healthy, non-smokers. Periodontally stable after therapy. One- or two-wall intraosseous defect associated with gingival recession.	Surgical technique TCAF + CTG + EMD + DFDBA	12 months	PD, CAL, GR, IDF, RC, TP-D

Authors	Design	Study Population	Treatment	Follow-up Time	Clinical and Radiographic Outcomes
Elfana et. al. 2022[15]	Case report	24-year-old female patient, systemically healthy, non-smoker. Tooth with mesial and distal pockets, slight extrusion, mesial diastema, slight mobility; radiographically, an intraosseous defect was observed.	Surgical technique CAF + CTG + xenograft	12 months	PD, CAL, GR, IDF, PRC, TP-D

Abbreviations: KTH, keratinized tissue height; RC, root coverage; PRC, partial root coverage; CTG, connective tissue graft; CAF, coronally advanced flap; DBBM, deproteinized bovine bone material; DFDBA, demineralized freeze-dried bone allograft; TP-D, tip of papilla–contact point distance; EMD, enamel matrix derivative; KTG, keratinized tissue gain; CAL, clinical attachment level; NIPSA, Nonincised Papillae Surgical Approach; PD, probing depth; IDF, intraosseous defect fill; GR, gingival recession; SFA, single flap approach; TCAF, Tunneled Coronally Advanced Flap.

PROBING DEPTH

In the seven case reports analyzed,[12–16,18,19] the mean initial PD was 7.22 ± 2.19 mm, which decreased to 4.48 ± 2.25 mm after surgical interventions. A retrospective cohort study compared a regenerative approach with CTG versus a control group, with initial PD values of 8.2 ± 2.4 mm and 7.9 ± 1.8 mm, respectively. Both groups showed similar reductions in PD (mean 4.8 ± 2.0 mm with CTG and 4.3 ± 1.8 mm without CTG), with no significant differences at 6 months.[20] A case series with 12 patients evaluated the combination of CTG, enamel matrix derivatives (EMD), and bone substitutes. The initial PD of 7.8 ± 1.5 mm decreased to 4.9 ± 1.6 mm after 12 months.[17]

CLINICAL ATTACHMENT LEVEL

In the case reports,[12–16,18,19] an average gain of 5.58 ± 2.48 mm was observed in CAL, with a reduction in attachment loss from 8.92 ± 7.72 mm to 3.4 ± 1.01 mm. In the case series,[17] the gain in CAL was 5.1 ± 1.1 mm, with a final CAL of 4.8 ± 1.1 mm after 12 months. In the retrospective cohort study,[20] both groups showed significant improvements in CAL, with an attachment gain of 4 mm in the test group and 3.2 mm in the control group, with no significant difference between them.

GINGIVAL RECESSION

In the seven case reports, the initial mean GR was 1.74 ± 1.49 mm, which decreased to 0.46 ± 0.65 mm, with an average gain of 0.22 ± 1.66 mm.[12–16,18,19] In the retrospective cohort study,[20] the test group achieved a reduction of 1.2 ± 1.1 mm in GR, while the control group showed a reduction of 0.4 ± 1.2 mm. In the case series,[17] GR decreased from 2.3 ± 1.8 mm to 1.7 ± 1.5 mm. Most studies demonstrated partial root coverage, whereas three reported complete coverage.[14,18,19]

KERATINIZED TISSUE

Regarding keratinized tissue, two studies[18,19] reported a significant increase in its height, with improvements of 1.62 ± 0.47 mm and 3 mm, respectively. One study described an increase in height of 3.5 ± 2.12 mm, though without specific data on thickness.[12] Other studies reported improvements in gingival phenotype and tissue thickness, but without quantitative data.[14,17,20] In a retrospective cohort study,[20] the mean height of keratinized tissue increased by 1.35 ± 2.2 mm, and 100% of patients treated with the bilaminar technique were classified as having a thick phenotype at 6 months.

DISTANCE BETWEEN THE CONTACT POINT AND PAPILLA APEX

Only four studies reported on the distance between the contact point and papilla apex, with a mean initial distance of 2.6 ± 1.89 mm. After treatment, a mean reduction of 1.5 ± 1.56 mm was achieved, resulting in a final distance of 1.3 ± 1.68 mm.[12,16–18]

RADIOGRAPHIC ANALYSIS

Seven studies evaluated intraosseous defect fill during follow-up, reported dichotomously (yes/no).[12,14–16,18–20] The longest follow-up was reported in case 1 of one study,[19] with controls at 36 months, which showed radiographic stability and bone fill. Other studies reported bone fill and increased radiopacity at 12 months,[12,14–16,18] while one cohort study presented results at 6 months with visible bone fill.[20] Two studies did not provide radiographic data.[13,17]

BIOMATERIALS AND BIOLOGICAL AGENTS

Eight studies included the use of EMD in their surgical protocols,[12–14,16–20] of which two applied it without bone grafting.[13,16] Five studies combined EMD with various grafting materials, such as xenograft[12,16,17,20] or allograft,[14] while one study reported the use of xenograft as monotherapy.[15]

Table 2. Clinical outcomes of case reports

Author/Year	Study Design	Number of Patients	Number of Teeth	Follow-up (months)	Biomaterials	Clinical Outcomes								
						PD (mm)			CAL(mm)			GR (mm)		
						Initial	Final	Δ	Initial	Final	Δ	Initial	Final	Δ
Zuchelli et. al 2014[18]	Case report	2	4	12	EMD	5	3	-2	7	3	4	-2	0	-2
						3	3	0	4	3	2	-1	0	-1
						9	2	-7	10	2	8	-1	0	-1
						3	2	-1	4	3	1	-1	-1	0
Santoro et. al. 2016[12]	Case reports	2	2	24	EMD, Xenograft	9	3	-6	12	5	7	-3	-1	-2
						10	3	-7	13	5	8	-3	-1	-2
Zuchelli et. al. 2017[19]	Case reports	2	2	24	EMD	11	3	-8	12	3	9	-1	0	1
						8	2	-6	9	2	7	-1	0	1
						8	3	-5	8	3	5	0	0	0
						9	3	-6	9	9	6	0	0	0
						3	3	0	3	3	0	0	0	0
						5	2	-3	8	2	6	-3	0	3
						10	4	-6	10	4	6	0	0	0
Succhelli et. al. 2016[13]	Case report	1	2	6	EMD	7,5	2	-5,5	14	4	10	-6,5	-2	4,5
						7	2	-5	11	3	8	-4	-1	3
Mourlaas et. al. 2022[14]	Case reports	3	4	12	EMD, Allograft (DFDBA)	8	3	-5	10	5	5	-1	0	-1
						6	3	-3	8	3	5	-2	0	-2
						8	2	-6	9	2	7	-1	0	-1
						7	-	-	8	-	-	-3	-	-

Author/Year	Study Design	Number of Patients	Number of Teeth	Follow-up (months)	Biomaterials		Clinical Outcomes								
							PD (mm)			CAL(mm)			GR (mm)		
							Initial	Final	Δ	Initial	Final	Δ	Initial	Final	Δ
Moreno et. al. 2019[16]	Case report	4	4	12	EMD, Xenograft		8	3	-5	9	5	4	-1	-1	0
							7	2	-5	9	3	6	-2	-1	1
							9	3	-6	12	5	7	-3	-2	1
							8	3	-5	9	3	6	-1	0	1
Elfana et. al. 2022[15]	Case report	1	1	12	Xenograft	Mesial	7	3	-4	9	4	5	-2	-1	1
						Distal	5	4	-1	6	4	2	-1	0	1

Abbreviations: DFDBA, demineralized freeze-dried bone allograft; EMD, enamel matrix derivative; CAL, clinical attachment level; PD, probing depth; GR, recession.

Table 3. Clinical outcomes of retrospective cohort and case series

Author/Year	Study design	Number of patients	Number of teeth	Follow-up (months)	Biomaterials	Resultados Clínicos								
						PD (mm)			CAL (mm)			REC (mm)		
						Inicial	Final	Δ	Inicial	Final	Δ	Inicial	Final	Δ
Trombelli et. al. 2016[20]	Retrospective cohort	30	15	6	EMD, Xenograft	8,2 ±2,4	3,4 ±0,8	4,8 ±2,0	10,9 ±2,9	6,9 ±2,3	4,0 ±1,5	2,0 ±1,8	3,2 ±2,2	1,2 ±1,1
						7,9 ±1,8	3,6 ±0,8	4,3 ±1,8	10,0 ±2,3	6,8 ±1,6	3,2 ±1,5	2,0 ±1,7	4,2 ±1,5	0,4 ±1,2
Bravard et. al. 2022[12]	Case series	12	12	12	EMD, Xenograft	7,8 ±1,5	2,9 ±0,7	4,9 ±1,6	9,9 ±2,1	4,8 ±1,1	5,1 ±1,8	2,3 ±1,8	1,7 ±1,5	0,6 ±1,0

Abbreviations: EMD, enamel matrix derivative.

CRITICAL QUALITY ANALYSIS

A breakdown of the critical quality analysis of the included studies, according to study type, is presented below. Overall, the studies demonstrated good methodological quality and a low risk of bias.

Table 4. Critical Appraisal Checklist for Case Reports

JBI Critical Appraisal Checklist for Case Reports[11]	Zuchelli et. al 2014[18]	Trombelli et. al. 2016[20]	Santoro et. al. 2016[12]	Zucchelli et. al. 2016[13]	Zuchelli et. al. 2017[19]	Moreno et. al. 2019[16]	Bravard et. al. 2022[17]	Mourlaas et. al. 2022[14]	Elfana et. al. 2022[16]
Were patient's demographic characteristics described?	Yes	Yes	Yes	Yes	Yes	Yes	Yes	Yes	Yes
Was the patient's history described and presented as a timeline?	Yes	Yes	Yes	Unclear	Unclear	Unclear	Yes	Yes	Unclear
Was the current clinical condition of the patient described?	Yes	Yes	Yes	Yes	Yes	Yes	Yes	Yes	Yes
Were diagnostic tests or assessment methods and the results clearly described?	Yes	Yes	Yes	Yes	Yes	Yes	Yes	Yes	Yes
Was the intervention(s) or treatment procedure(s) described?	Yes	Yes	Yes	Yes	Yes	Yes	Yes	Yes	Yes
Was the post-intervention clinical condition described?	Yes	Yes	Yes	Yes	Yes	Yes	Yes	Yes	Yes
Were adverse events identified and described?	Yes	Yes	No	No	No	No	Yes	Yes	No
Does the case report provide takeaway lessons?	Yes	Yes	Yes	Yes	Yes	Yes	Yes	Yes	Yes

Table 5. Critical Appraisal Checklist for Case Series and Cohort Studies

JBI Critical Appraisal Checklist for Case Series[11]	Zuchelli et. al 2014[18]	Critical Appraisal Checklist for Cohort Studies[11]	Santoro et. al. 2016[12]
Were the two groups similar and recruited from the same population?	Unclear	Were there clear criteria for inclusion in the case series?	Yes
Was the condition measured similarly to assign participants to both exposed and unexposed groups?	Yes	Was the condition measured in a standard, reliable way for all participants included in the case series?	Yes
Was the condition measured in a valid and reliable way?	Yes	Were valid methods used for identification of the condition for all participants included in the case series?	Yes
Were confounding factors identified?	Unclear	Did the case series have consecutive inclusion of participants?	Yes
Were strategies to handle confounding factors stated?	No	Did the case series have complete inclusion of participants?	Yes
Were participants free of the outcome at the start of the study (or at the moment of exposure)?	Yes	Was there clear reporting of the demographics of the participants in the study?	Yes
Were outcomes measured in a valid and reliable way?	Yes	Was there clear reporting of clinical information of the participants?	No
Was follow-up time reported and sufficient for outcomes to occur?	Yes	Were the outcomes or follow-up results of cases clearly reported?	Yes
Was follow-up complete, and if not, were reasons for loss to follow-up described and explored?	Yes	Was there clear reporting of the presenting site(s)/clinic(s) demographic information?	Unclear
Were strategies used to address incomplete follow-up?	Yes	Was statistical analysis appropriate?	Yes
Was statistical analysis appropriate?	Yes		

Discussion

This review focused on analyzing the clinical and radiographic outcomes of surgical treatment of intraosseous defects. The findings indicate that combined therapy—namely the use of CTG with EMD and/or xenograft, together with different flap designs—is an effective strategy for the treatment of intraosseous defects associated with gingival recession.

One of the main findings is the improvement of periodontal parameters, with a reduction in PD and a gain in CAL, following regenerative surgical interventions that combine the use of CTG with bone grafting and/or EMD. Moreover, these results were shown to remain stable during the follow-up period.[12–20] In line with this, a

systematic review reported a decrease in PD of 4.22 ± 1.2 mm and a gain in CAL of 3.76 ± 10.07 mm when using EMD and bone grafting.[21] However, when compared with our study, the results obtained by complementing regeneration with CTG showed a greater reduction in PD and a superior gain in CAL. This difference could be explained by the incorporation of CTG in the surgical treatment of intraosseous defects, as it improves the characteristics of the overlying flap and contributes to defect stabilization by acting as a missing wall, supporting both the bone graft and the forming clot.[15,17]

Currently, the surgical treatment considered the gold standard for intraosseous defects is GTR or the application of EMD in combination with papilla-preserving flaps, rather than monotherapies or procedures limited to flap debridement.[7] Therefore, it is important to analyze the role of EMD, as it is one of the most widely used biologic agents in combined therapies with bone grafts.[12,13,16,17,20] Bone grafts provide stability and maintain space within the defect, whereas EMD stimulates the release of growth factors that promote the growth, differentiation, and proliferation of cementoblasts and osteoblasts.[22] A recent systematic network review reinforced the importance of combination therapies, reporting that the use of bone grafts together with biologic agents—such as EMD, fibrin-rich plasma, and recombinant platelet-derived growth factor (rhPDGF-BB)—significantly enhances clinical and radiographic outcomes. However, the review also noted that fibrin-rich plasma and rhPDGF-BB may offer greater potential than EMD in maintaining gingival margin stability when combined with xenografts.[23]

On the other hand, it is important to emphasize that the effectiveness of PD reduction may vary depending on the anatomical configuration and depth of intraosseous defects, which may respond differently to regenerative therapies.[24] For this reason, multiple therapeutic approaches are needed to maximize clinical and radiographic outcomes in complex cases. In this context, combination therapies incorporating CTG with biologic agents and bone grafts may be essential to achieving long-term stability in both hard and soft tissues.[15,17] The addition of CTG has also been shown to reduce post-treatment recurrence of GR. Further improvements have been reported through increases in the thickness and width of keratinized tissue.[15,20] In some cases, preservation of papillary height was achieved using minimally invasive techniques with papilla preservation, which were also associated with enhanced bone regeneration and stable long-term clinical outcomes.[17]

In this study, both complete[14,18,19] and partial[12, 13, 15–17, 20] root coverage of gingival recessions were observed. This variability may be primarily related to anatomical characteristics of the defects, since the presence of dehiscences or severe defects in buccal or proximal areas (≥ 5 mm) can compromise the vascular supply to the CTG, thereby limiting its success.[15] Moreover, when the apico-coronal height of a buccal defect exceeds 5 mm, it may be unfeasible to fully replace the missing wall with CTG, as extracting larger grafts from the donor site could significantly increase patient morbidity.[12]

It is also important to highlight that the CAF was among the most frequently used flap designs in the studies addressing intraosseous defects.[12–15,17,18] As is well established, CAF combined with CTG has proven effective in achieving complete root coverage in Miller Class I and II recessions,[15,18,19] due to the coronal advancement capacity of CAF and the potential of CTG beneath the flap to revascularize, resulting in favorable outcomes.[19,25] However, in Miller Class III recessions—characterized by loss of interproximal bone support and, particularly, when intraosseous defects are present—outcomes are more variable and less predictable. This is related to local factors such as inadequate interproximal bone support, unfavorable tooth position, and reduced papillary height,[25] features that commonly accompany intraosseous defects and limit the predictability of achieving complete root coverage.[13]

Finally, it is important to emphasize that one of the key factors in this study is the surgeon's ability to design and manage the flap. This is fundamental, as the elevation of mixed-thickness flaps and the preservation of anatomic papillae were directly correlated with improved coverage and long-term stability.[14,18,19] Moreover, studies employing papilla preservation techniques proved effective in preventing the development of secondary gingival recessions,[12–16,18–20] which is particularly critical in esthetic areas, where minimally invasive designs play a pivotal role.[6] In addition, current trends in the field are moving toward approaches that integrate elements of periodontal regeneration with periodontal plastic surgery. For example, concepts combining tunneling with the full papilla preservation flap have been described, offering a less invasive tissue management strategy while adding biological potential for stability of interdental and buccal tissues.[14,26]

The results of this study should be interpreted with caution, considering that most of the available evidence comes from clinical case series and case reports, generally involving small sample sizes and follow-up periods of no more than two years, which are considered low-level evidence. Nonetheless, the critical appraisal of the included studies yielded favorable outcomes. Another limitation was the wide variability in terminol-

ogy used to describe the techniques, which hindered the development of more efficient search strategies. Despite these constraints, the findings are encouraging, as they are grounded in the combination of papilla preservation techniques, apical access, and periodontal plastic surgery procedures such as CTG and CAF—techniques that, individually, are supported by a large body of high-quality evidence.

For future studies, it is essential to first analyze the characteristics and types of intraosseous defects—including whether they are containable, their depth, defect angle, the number of remaining walls, extent, and the type of associated tooth. This evaluation determines the regenerative predictability of the defect and establishes clear treatment criteria. Another key parameter to document and analyze is the soft tissue, particularly keratinized tissue in both height and thickness, which enables precise and objective outcome assessment. Furthermore, radiographic analysis using cone beam computed tomography should be incorporated, as it provides more accurate and detailed visualization of defect anatomy, thereby improving the quality of evaluations and inter-study comparisons.

Conclusions

Combination therapy for intraosseous defects, consisting of CTG with EMD and/or bone grafting, improves periodontal parameters through a decrease in PD and a gain in CAL, along with radiographic bone fill and additional improvements in apico-coronal soft tissue dimensions and gingival thickness. These outcomes have the potential to enhance both the prognosis and the comfort of treated teeth.

REFERENCES

1. Sanz M, Herrera D, Kebschull M, Chapple I, Jepsen S, Beglundh T, Sculean A, Tonetti MS; EFP Workshop Participants and Methodological Consultants. Treatment of stage I-III periodontitis-The EFP S3 level clinical practice guideline. J Clin Periodontol. 2020 Jul;47 Suppl 22(Suppl 22):4-60. doi: 10.1111/jcpe.13290.

2. Aimetti M, Fratini A, Manavella V, et al. Pocket resolution in regenerative treatment of intrabony defects with papilla preservation techniques: A systematic review and meta-analysis of randomized clinical trials. J Clin Periodontol. 2021;48(6):843-858. doi:10.1111/jcpe.13428

3. Tsai SJ, Ding YW, Shih MC, Tu YK. Systematic review and sequential network meta-analysis on the efficacy of periodontal regenerative therapies. J Clin Periodontol. 2020 Sep;47(9):1108-1120. doi: 10.1111/jcpe.13338.

4. Cortellini P, Cortellini S, Bonaccini D, Tonetti MS. Modified minimally invasive surgical technique in human intrabony defects with or without regenerative materials-10-year follow-up of a randomized clinical trial: Tooth retention, periodontitis recurrence, and costs. J Clin Periodontol. 2022;49(6):528-536. doi:10.1111/jcpe.13627

5. Stavropoulos A, Bertl K, Spineli LM, Sculean A, Cortellini P, Tonetti M. Medium- and long-term clinical benefits of periodontal regenerative/reconstructive procedures in intrabony defects: Systematic review and network meta-analysis of randomized controlled clinical studies. J Clin Periodontol. 2021;48:410–30. DOI: 10.1111/jcpe.13409

6. Ossa-Sherman M, Araya-Contador R, Segovia-Chamorro J. Tratamiento regenerativo de defectos intraóseos mediante colgajos mínimamente invasivos: Revisión sistemática exploratoria. Odontoestomatologia. 2023;24(40). DOI: 10.22592/ode2022n40e318

7. Nibali L, Koidou VP, Nieri M, Barbato L, Pagliaro U, Cairo F. Regenerative surgery versus access flap for the treatment of intrabony periodontal defects: A systematic review and meta analysis. J Clin Periodontol. 2020;47(Suppl 22):320–51. DOI: 10.1111/jcpe.13237

8. Rasperini G, Tavelli L, Barootchi S, McGuire MK, Zucchelli G, Pagni G, Stefanini M, Wang HL, Giannobile WV. Interproximal attachment gain: The challenge of periodontal regeneration. J Periodontol. 2021 Jul;92(7):931-946. doi: 10.1002/JPER.20-0587.

9. Rasperini G, Acunzo R, Barnett A, Pagni G. The Soft Tissue Wall Technique for the Regenerative Treatment of Non-contained Infrabony Defects: A Case Series. Int J Periodontics Restorative Dent. 2013;33(3):e79–87. DOI: 10.11607/prd.1628.

10. Tricco AC, Lillie E, Zarin W, O'Brien KK, Colquhoun H, Levac D, et al. PRISMA extension for scoping reviews (PRISMA-ScR): Checklist and explanation. Ann Intern Med. 2018;169(7):467–73. DOI: 10.7326/M18-0850

11. Joanna Briggs Institute. Critical Appraisal Tools [Internet]. JBI. 2020. Available from: https://jbi.global/critical-appraisal-tools

12. Santoro G, Zucchelli G, Gherlone E. Combined regenerative and mucogingival treatment of deep intrabony defects associated with buccal gingival recession: Two case reports. Int J Periodontics Restorative Dent. 2016;36(6):849–57. DOI: 10.11607/prd.2764

13. Zucchelli G, Bentivogli V, Ganz S, Bellone P, Mazzotti C. The connective tissue graft wall technique to improve root coverage and clinical attachment levels in lingual gingival defects. Int J Esthet Dent. 2016;11(4):524–37. PMID: 27730223

14. Mourlaas J, Cortasse B, Vigouroux F, Dagba A. The tunnel wall approach and enamel matrix derivative to cover exposed roots and improve clinical attachment levels in Cairo Class III defects associated with an intrabony lesion in the anterior area: Three cases. Int J Periodontics Restorative Dent. 2023;43(1):95–102. DOI: 10.11607/prd.6352

15. Elfana A, Elbehwashy M. Periodontal regeneration using connective tissue graft wall and xenograft with coronally advanced flap in noncontained intrabony defects: A novel combination technique. J Indian Soc Periodontol. 2022;26(3):295–8. DOI: 10.4103/jisp.jisp_347_21

16. Moreno Rodríguez JA, Ortiz Ruiz AJ, Zamora GP, Pecci-Lloret M, Caffesse RG. Connective Tissue Grafts with Nonincised Papillae Surgical Approach for Periodontal Reconstruction in Noncontained Defects. Int J Periodontics Restorative Dent. 2019;39(6):781-787. doi:10.11607/prd.4282

17. Bravard M, Agossa K. Combination therapy with connective tissue graft, amelogenins, and bone substitutes for treatment of deep intrabony defects associated with gingival recession: 1 Year follow-up of 12 cases. Int J Periodontics Restorative Dent. 2022;42(3):321–9. DOI: 10.11607/prd.5479

18. Zucchelli G, Mazzotti C, Tirone F, Mele M, Bellone P, Mounssif I. The Connective Tissue Graft Wall Technique and Enamel Matrix Derivative to Improve Root Coverage and Clinical Attachment Levels in Miller Class IV Gingival Recession. Int J Periodontics Restorative Dent. 2014;34(5):601–9. DOI: 10.11607/prd.1978

19. Zucchelli G, Mounssif I, Marzadori M, Mazzotti C, Felice P, Stefanini M. Connective Tissue Graft Wall Technique and Enamel Matrix Derivative for the Treatment of Infrabony Defects: Case Reports. Int J Periodontics Restorative Dent. 2017;37(5):673–81. DOI: 10.11607/prd.3083

20. Trombelli L, Simonelli A, Minenna L, Rasperini G, Farina R. Effect of a Connective Tissue Graft in Combination With a Single Flap Approach in the Regenerative Treatment of Intraosseous Defects. J Periodontol. 2017;88(4):348–56. DOI: 10.1902/jop.2016.160471

21. Matarasso M, Iorio-Siciliano V, Blasi A, Ramaglia L, Salvi GE, Sculean A. Enamel matrix derivative and bone grafts for periodontal regeneration of intrabony defects. A systematic review and meta-analysis. Clin Oral Investig. 2015;19(7):1581-1593. doi:10.1007/s00784-015-1491-7

22. Miron RJ, Sculean A, Cochran DL, Froum S, Zucchelli G, Nemcovsky C, et al. Twenty years of enamel matrix derivative: The past, the present and the future. J Clin Periodontol. 2016;43(8):668–83. DOI: 10.1111/jcpe.12546

23. Tavelli L, Chen CY, Barootchi S, Kim DM. Efficacy of biologics for the treatment of periodontal infrabony defects: An American Academy of Periodontology best evidence systematic review and network meta-analysis. J Periodontol. 2022;93(12):1803–26. DOI: 10.1002/JPER.22-0120

24. Yang Z, Yu Q, Ren L, Wang H, Zhu L. Efficacy of OFD with EMD for treatment of periodontal defects: A systematic review and meta-analysis. Oral Dis. 2024;30(2):250–70. DOI: 10.1111/odi.15029

25. Chambrone L, Sukekava F, Araújo MG, Pustiglioni FE, Chambrone LA, Lima LA. Root coverage procedures for the treatment of localized recession-type defects: A Cochrane systematic review. J Periodontol. 2010;81(4):452–78. DOI: 10.1902/jop.2010.090540

26. Rasperini G, Kazarian E, Aslan S. Coronally Advanced Entire Papilla Preservation (CA-EPP) Flap in the Treatment of an Isolated Intrabony Defect to Promote Buccal and Interproximal Soft Tissue Stability: Case Reports. Int J Periodontics Restorative Dent. 2024;44(1):9–16. DOI: 10.11607/prd.6851

Conflict of interest statement

The authors declare no conflict of interest.

Funding source

This research did not receive any specific grants from funding agencies in the public, commercial, nor nonprofit sectors.

Author Contributions

AUTHORS' FULL NAME	ACADEMIC COLLABORATION													
	1	2	3	4	5	6	7	8	9	10	11	12	13	14
Bernardita Cattarinich-Araya			x		x	x	x	x		x	x			x
Camila Serrano-Spalinger			x		x	x	x	x		x	x			x
Enzo Niccoli-Merello						x	x					x	x	
Jaime Segovia-Chamorro	x	x		x		x	x	x	x	x		x	x	

1. Project Administration
2. Funding Acquisition
3. Formal Analysis
4. Conceptualization
5. Data Curation
6. Writing - Review and Editing
7. Research
8. Methodology
9. Resources
10. Writing - Original Draft Preparation
11. Software
12. Supervision
13. Validation
14. Visualization

Acceptance note:
This article was approved by the journal editor, Dr. Natalia Tancredi Cueto, MSc.