Facultad de Odontología

Odontoestomatología
DOI: 10.22592/ode2026n47e425

Surgical Fenestration of an Impacted Third Molar in a Patient with Supernumerary Teeth

CASE REPORT

Fenestración quirúrgica de tercer molar incluido en paciente con dientes supernumerarios

Fenestração cirúrgica de terceiro molar incluso em paciente com dentes supranumerários

Abstract

Tooth impaction is a common condition affecting both permanent and supernumerary teeth, with an incidence ranging from 3.1% to 17%. The case of a 19-year-old patient with an impacted mandibular third molar and a supernumerary tooth is presented, whose eruption was guided using an orthodontic button to replace a second molar with a poor prognosis. The surgical intervention involved fenestration of the third molar and extraction of the affected second molar, with placement of an L-PRF membrane to promote bone regeneration. Histopathological findings showed a dentigerous cyst. After a three-year follow-up period, tooth #48 had improved its position. Although the patient discontinued orthodontic treatment, her oral health remained stable. This case highlights the effectiveness of combined surgical and orthodontic techniques in managing impacted teeth and suggests that controlled eruption of third molars may be a viable alternative for preserving natural dentition.

AUTHORS

Araceli Chamorro V.[1]
Sofia Escobar R.[1]
Francisco Escala P.[1]

CORRESPONDENCE
Araceli Chamorro Vega
apchamorro@miuandes.cl

Received: May 26, 2025
Accepted: September 23, 2025

CC BY

Keywords: Supernumerary tooth, Fenestration, Impacted tooth, Orthodontic treatment

[1] Universidad de los Andes, Santiago de Chile

Resumen

La retención dentaria es un fenómeno común que afecta dientes permanentes y supernumerarios, con una incidencia entre el 3.1% y el 17%. Se presenta el caso de una paciente de 19 años con un tercer molar inferior incluido y un diente supernumerario, cuya erupción fue guiada mediante un botón ortodóncico para reemplazar un segundo molar con mal pronóstico. La intervención incluyó la fenestración del tercer molar y la extracción del segundo molar afectado, utilizando una membrana de L-PRF para promover la regeneración ósea. Los hallazgos histopatológicos mostraron un quiste Dentígero. Tras tres años de seguimiento, la pieza 48 mejoró su posición, y aunque la paciente abandonó el tratamiento ortodóntico, su salud dental se mantuvo estable. Este caso resalta la efectividad de las técnicas quirúrgicas y ortodóncicas en el manejo de dientes impactados y sugiere que la erupción controlada de terceros molares puede ser una alternativa viable para conservar la dentición.

Palabras clave: Dientes supernumerarios, Fenestración, Dientes Impactados, Tratamiento Ortodóntico

Resumo

A retenção dentária é um fenômeno comum que afeta dentes permanentes e supranumerários, com uma incidência entre 3,1% e 17%. Apresenta-se o caso de uma paciente de 19 anos com um terceiro molar inferior incluso e um dente supranumerário, cuja erupção foi guiada por meio de um botão ortodôntico para substituir um segundo molar com prognóstico desfavorável. A intervenção incluiu a fenestração do terceiro molar e a extração do segundo molar afetado, utilizando uma membrana de L-PRF para promover a regeneração óssea. Os achados histopatológicos revelaram um cisto dentígero. Após três anos de acompanhamento, o dente 48 melhorou sua posição e, embora a paciente tenha abandonado o tratamento ortodôntico, sua saúde bucal permaneceu estável. Este caso destaca a eficácia das técnicas cirúrgicas e ortodônticas no manejo de dentes inclusos e sugere que a erupção controlada de terceiros molares pode ser uma alternativa viável para a preservação da dentição.

Palavras-chave: Dentes supranumerários, Fenestração, Dentes inclusos, Tratamento ortodôntico

Introduction

Tooth impaction is a frequent finding in clinical practice and can affect both permanent and supernumerary teeth. Its prevalence varies considerably according to geographic region,[1] as demonstrated in multiple studies. Several authors have reported that the incidence of impacted teeth ranges from 3.1% to 17% of the population.[2]

The mandibular third molar is the tooth with the greatest tendency toward impaction, mainly due to lack of space.[3] Its clinical management depends on several factors, including its position, proximity to critical anatomical structures, and the condition of adjacent teeth. Among the therapeutic alternatives is surgical fenestration with orthodontic traction; a technique that guides molar eruption through the selective removal of bone and soft tissue, facilitating its progressive alignment within the dental arch.[4] However, the literature on third molar disimpaction and their potential use as substitutes for teeth with a poor prognosis remains limited. In this sense, the possibility of replacing a compromised second molar through the controlled eruption of a third molar represents an innovative strategy to preserve the patient's dentition and avoid more invasive treatments.

In this context, this case report describes the surgical management of an impacted mandibular third molar associated with a supernumerary tooth, whose eruption was guided using an orthodontic button with the objective of replacing a second molar with a poor prognosis. This case underscores the importance of a multidisciplinary approach to treatment planning, integrating surgical and orthodontic techniques to restore the patient's dental formula.

Background

A 19-year-old female patient, systemically healthy, was referred by an orthodontist from an external clinic for evaluation and management of third molars and associated supernumerary teeth. Intraoral examination revealed the absence of teeth #28, #48, and #47, and partial impaction of teeth #18 and #37 (**Figure 1**). A panoramic radiograph and a cone-beam computed

tomography (CBCT) scan were requested (**Figure 2** and **Figure 3**), which showed tooth #48 impacted near the basilar border and the mandibular canal, in mesioversion and impinging on tooth #47. A well-defined, corticated pericoronal osteolytic lesion was also observed. Tooth #47 was retained and in distoversion. Additionally, an inverted supernumerary molar was identified in the right mandibular ramus, with its crown in direct contact with that of tooth #47 ("kissing molars").

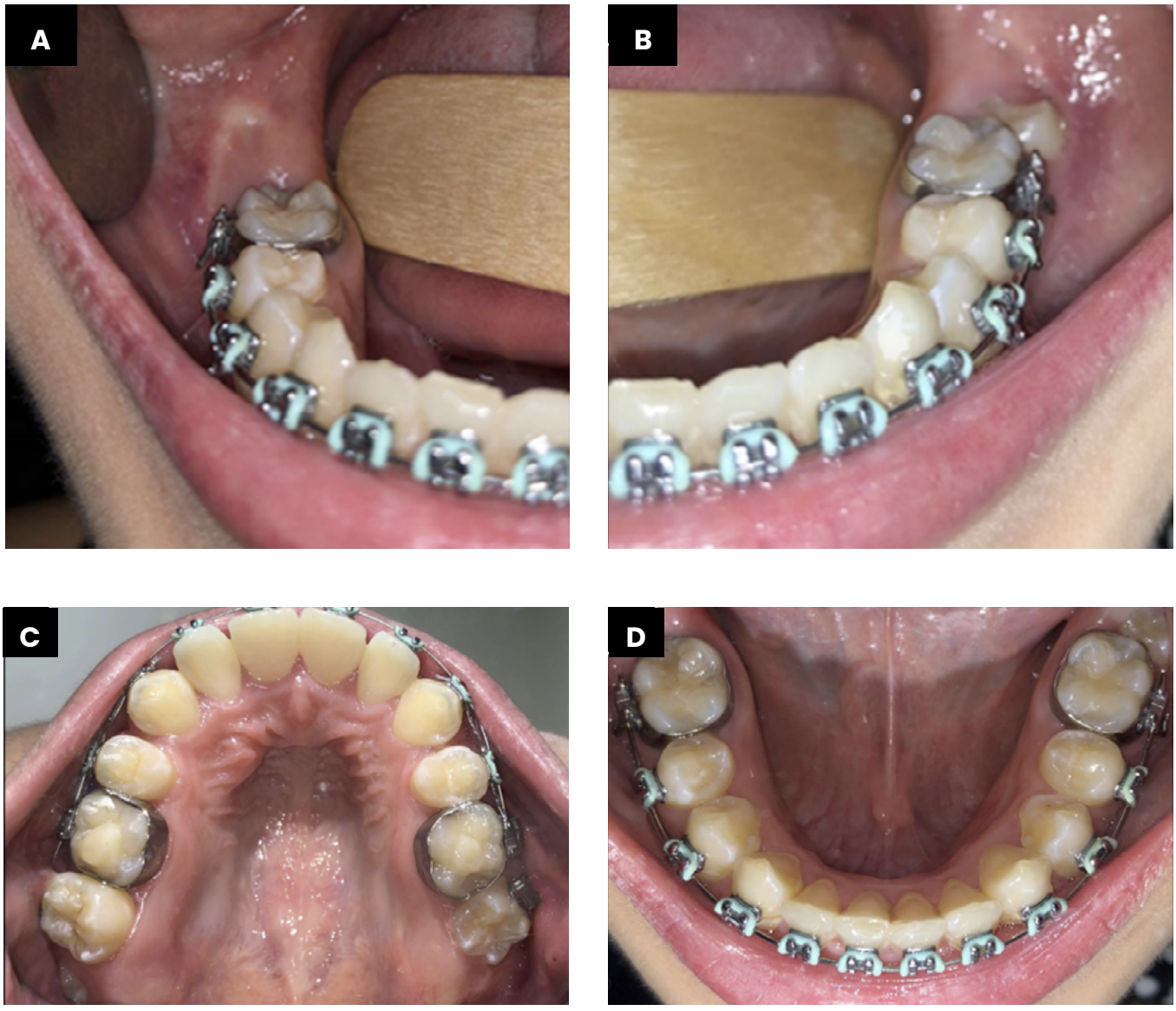

Figure 1. Preoperative intraoral photographs.
(A) Right side; (B) Left side; (C) Occlusal view of the maxilla; (D) Occlusal view of the mandible.



Figure 2. Preoperative panoramic radiograph.

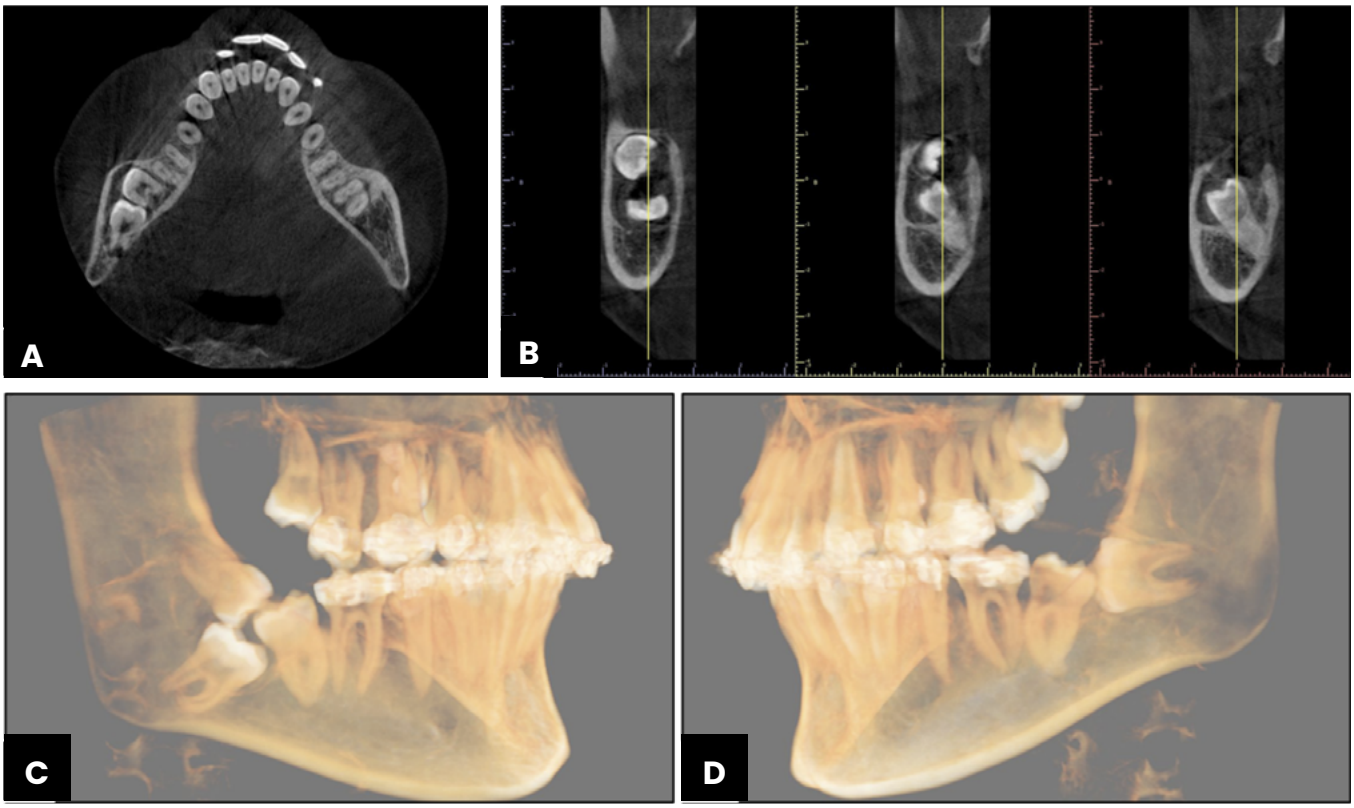

Figure 3. Preoperative CBCT.
(A) Axial section; (B) Coronal sections; (C) 3D reconstruction, right side; (D) 3D reconstruction, left side.**Figure 4.**

Description

SURGICAL TREATMENT

Because of the distal bone defect associated with tooth #47, extraction was indicated, along with surgical fenestration of tooth #48 and orthodontic traction to guide its eruption and replace the missing tooth. Given the complexity of the procedure and the number of extractions required, surgery was performed under general anesthesia. Extractions of teeth #18, #28, and #38, as well as the upper distomolars, were completed. In the right mandibular region, both the supernumerary molar and tooth #47 were extracted. An excisional biopsy of the pericoronal lesion associated with tooth #47 was performed and submitted for histopathologic examination. Subsequently, a peripheral osteotomy of the molar was carried out, along with cortical perforations. An orthodontic button was cemented on the occlusal surface of tooth #48 and traction was applied using a bayonet wire. An L-PRF membrane was placed over the bone defect to promote local bone regeneration (**Figure 4**). The site was sutured with 3-0 nylon. The procedure was completed without surgical or anesthetic complications.

FOLLOW-UP AND RESULTS

Histopathologic analysis revealed findings consistent with a dentigerous cyst. The patient remained under orthodontic follow-up for three years. At the three-year control visit with the Oral and Maxillofacial Surgery department, she presented without orthodontic appliances. Tooth #28 was absent, and tooth #37 was partially erupted and buccally displaced (**Figure 5**). A control panoramic radiograph (**Figure 5F**) showed tooth #48 covered by mucosa, positioned more coronally compared with the initial image, and no evidence of lesion recurrence. The patient was advised to continue orthodontic treatment; however, she voluntarily chose to discontinue it.

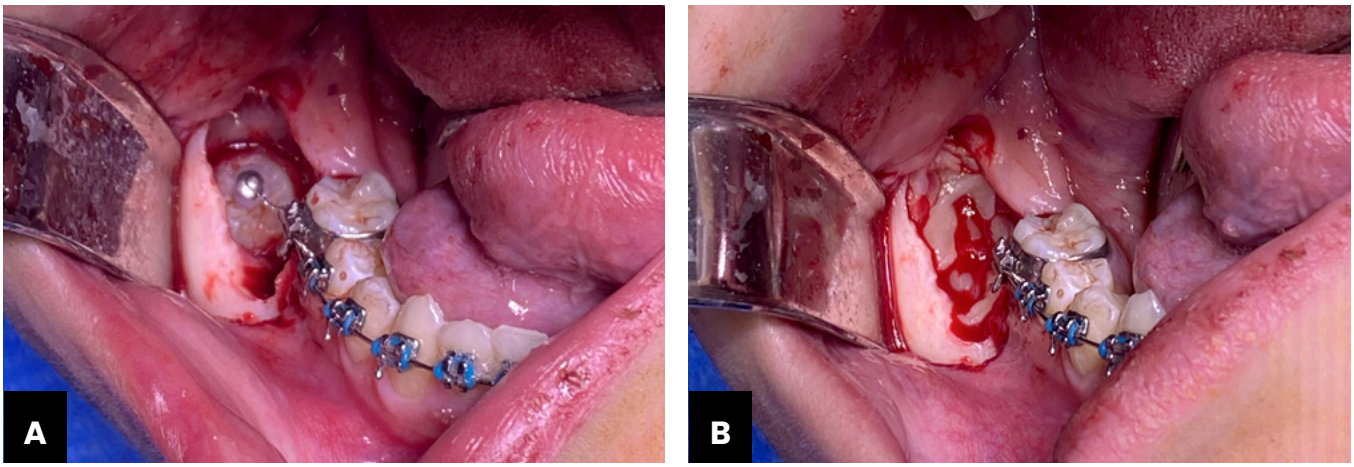

Figure 4. FIntraoperative photographs.
(A) Tooth #48 with orthodontic button and traction chain in place; (B) L-PRF membrane covering the bone defect.



Figure 5. Intraoral photographs after three years of follow-up. **(A)** In occlusion, right lateral view; **(B)** In occlusion, frontal view; **(C)** In occlusion, left lateral view;







Figure 5. (continuation) Intraoral photographs after three years of follow-up. **(D)** Occlusal view of the maxilla; **(E)** Occlusal view of the mandible; **(F)** Panoramic radiograph after three years of follow-up.

Discussion

The use of combined surgical and orthodontic techniques for third molar traction has been widely documented in the literature for various purposes. Alessandri et al. reported a case of orthodontic traction of a third molar performed to preserve the second molar and prevent its periodontal deterioration[4]. Likewise, Montevecchi et al. demonstrated significant improvements in periodontal parameters, such as reduced probing depth and recovery of clinical attachment levels, in the distal area of the second molar following extraction of a third molar previously subjected to orthodontic traction[5]. Furthermore, third molar traction has also been proposed as a pre-extraction technique to minimize the risk of paresthesia, particularly when the roots are in close proximity to the mandibular canal[6]. In this case, given the existing bone defect, the decision was made to extract the second molar and replace it with a third molar brought into position through orthodontic traction. Regarding the anchorage system, several variations of the technique have been described, including the use of traction chains, elastics, and anchorage to adjacent brackets or mini-implants/micro-screws[7-9].

Another relevant concept is the "Regional Acceleratory Phenomenon" (RAP), described by Frost in 1983, which forms the biological basis of Accelerated Osteogenic

Orthodontics (AOO). RAP is defined as a localized physiological response that transiently accelerates metabolic and tissue repair processes in response to surgical or noxious stimuli[10]. In orthodontics, RAP decreases the biomechanical resistance of the alveolar bone, thereby facilitating tooth movement[11-13]. Although, strictly speaking, AOO was not applied in this case, maneuvers such as peripheral osteotomy of the bone surrounding the impacted third molar and cortical microperforations were performed, both based on the same biological principle. Considering that the peak expression of RAP occurs between four and eight weeks after stimulation[11-13], the orthodontist was advised to initiate traction within a few days of the surgical procedure.

Although this case showed a favorable evolution regarding the displacement of the impacted molar, it is important to note that the patient voluntarily discontinued orthodontic treatment, preventing achievement of the final therapeutic goal: bringing the third molar to the occlusal plane. This lack of adherence represents a significant limitation when assessing clinical success and should be carefully considered when indicating this type of approach, particularly in patients with a history of poor cooperation.

Another key point concerns the decision to preserve a mandibular third molar despite its association with a dentigerous cyst. In this case, the cyst was completely removed through excisional biopsy, and the tooth was preserved due to its caudal location in the mandible. Extraction of the molar carried a high risk of complications, including postoperative infection and even mandibular fracture. Therefore, a conservative strategy based on controlled orthodontic traction was deemed to provide a more favorable risk–benefit balance. Nevertheless, this decision should be evaluated on a case-by-case basis, considering anatomical and biological factors as well as the predictability of orthodontic follow-up.

Regarding the replacement of permanent teeth with poor prognosis using impacted third molars, the scientific evidence remains limited. However, this case demonstrated stable outcomes after a three-year follow-up, supporting the feasibility of this therapeutic approach. A unique aspect of this case was the simultaneous presence of several clinical factors not previously reported in the literature: a supernumerary tooth located mesially and superior to the third molar, distal inclination of the second molar, and a dentigerous cyst associated with the impacted third molar. These characteristics grant this report additional value as a clinical reference for managing similarly complex situations.

Conclusions

Although orthodontic treatment was not completed in this case, progressive displacement of the impacted third molar was observed. This finding suggests that orthodontic traction of retained molars is technically feasible under certain clinical conditions. However, the patient's voluntary discontinuation of treatment prevented a full assessment of the functional outcomes, representing an important limitation.

In this context, surgical fenestration combined with orthodontic traction constitutes a valid therapeutic alternative for managing complex dental inclusions—particularly in cases where more invasive procedures, such as third molar extraction with potential complications, are to be avoided. Nevertheless, its indication should be based on a thorough evaluation of the local anatomy, the prognosis of the compromised tooth, and, most importantly, the anticipated level of patient adherence.

REFERENCES

1. Litsas G, Acar A. Tooth impaction: etiology, clinical implications and treatment. *Clin Dent Res.* June 2011;35(2):61-67.

2. Macias-Escalada E, Cobo-Plana J, Carlos-Villafranca F de, Pardo-López B. Abordaje ortodóncico quirúrgico de las inclusiones dentarias. RCOE. febrero de 2005;10(1):69-82.

3. Lambade P, Dawane P, Mali D. Assessment of Difficulty in Mandibular Third Molar Surgery by Lambade-Dawane-Mali's Index. J Oral Maxillofac Surg. junio de 2023;81(6):772-9.

4. Alessandri Bonetti G, Incerti Parenti S, Checchi L. Orthodontic extraction of mandibular third molar to avoid nerve injury and promote periodontal healing. J Clin Periodontol. agosto de 2008;35(8):719-23.

5. Montevecchi M, Incerti Parenti S, Checchi V, Palumbo B, Checchi L, Alessandri Bonetti G. Periodontal healing after 'orthodontic extraction' of mandibular third molars: A retrospective cohort study. Int J Oral Maxillofac Surg. septiembre de 2014;43(9):1137-41.

6. Alessandri Bonetti G, Bendandi M, Laino L, Checchi V, Checchi L. Orthodontic Extraction: Riskless Extraction of Impacted Lower Third Molars Close to the Mandibular Canal. J Oral Maxillofac Surg. diciembre de 2007;65(12):2580-6.

7. Park W, Park JS, Kim YM, Yu HS, Kim KD. Orthodontic extrusion of the lower third molar with an orthodontic mini implant. Oral Surg Oral Med Oral Pathol Oral Radiol Endodontology. octubre de 2010;110(4):e1-6.

8. Wang Y, He D, Yang C, Wang B, Qian W. An easy way to apply orthodontic extraction for impacted lower third molar compressing to the inferior alveolar nerve. J Cranio-Maxillofac Surg. abril de 2012;40(3):234-7.

9. Jung S, Lee JH, Huh J, Park W. Orthodontic Extrusion of Mandibular Third Molar With a Miniscrew and Cross-Arch Elastic. J Oral Maxillofac Surg. julio de 2021;79(7):1422.e1-1422.e8.

10. Frost HM. The regional acceleratory phenomenon: a review. Henry Ford Hosp Med J. 1983;31:3–9.

11. Cano J, Campo J, Bonilla E, Colmenero C. Accelerated orthodontic techniques: a review of current literature. J Clin Exp Dent. 2012 Feb;4(1):e54–e59.

12. Amit G, Kalra J, Pankaj B, Suchinder S, Parul B. Periodontal accelerated osteogenic orthodontics: a review. Clin Exp Dent. 2012 Dec;4(5):e292–e296.

13. Murphy K, Wilcko M, Wilcko W, Ferguson D. Periodontal accelerated osteogenic orthodontics: surgical technique with a selective alveolar decortication and bone grafting. J Oral Maxillofac Surg. 2009;67(10):2160–2166.

Data availability

All data supporting the findings of this study are included within the article

Conflict of interest statement

The authors declare no conflicts of interest.

Funding source

This research did not receive any specific grant from funding agencies in the public, commercial, or nonprofit sectors.

Ethics Committee

No ethics committee approval was required for this research. However, efforts were made to maintain patient privacy, and informed consent was obtained from the patient for publication.

AUTHORS' FULL NAME	ACADEMIC COLLABORATION													
	1	2	3	4	5	6	7	8	9	10	11	12	13	14
Araceli Chamorro V.	x			x		x				x				x
Sofía Escobar R.				x		x				x				x
Francisco Escala P.	x			x		x			x			x		

1. Project Administration
2. Funding Acquisition
3. Formal Analysis
4. Conceptualization
5. Data Curation
6. Writing - Review and Editing
7. Research
8. Methodology
9. Resources
10. Writing - Original Draft Preparation
11. Software
12. Supervision
13. Validation
14. Visualization

Acceptance note:
This article was approved by the journal editor, Dr. Natalia Tancredi Cueto, MSc.