

Utility of linear tomography in the localization of the inferior alveolar canal






INVESTIGATION

Utilidad de la tomografía lineal en la localización del conducto alveolar inferior

Utilidade da tomografia linear na localização do ducto alveolar inferior

Abstract

Objective. To evaluate the influence of x-ray tube current and voltage on the localization of the alveolar canal using linear tomography. **Material and Methods.** The sample consisted of 24 hemi-mandibles scanned with a linear tomography system using different combinations of kV and mA. The acquired images were processed using ImageJ software to obtain coronal sections, which were then evaluated by five observers. Diagnostic accuracy was assessed using the area under the curve (Az) from ROC (receiver operating characteristic) curves, analyzed with ROCKIT 1.1B software. The intra- and inter-observer Kappa indices were 0.79 and 0.71, respectively. **Results.** Higher Az values (0.912) were achieved using low kV (60 kV). When mA was varied, the highest Az value (0.911) was observed at 2 mA. **Conclusion.** The use of low x-ray tube current and voltage values is recommended.

 Juan Manuel González Mollo ¹
 Carolina Riera Laiño ²
 Rocío Mott Gutierrez ³
 Flavio Echeverria Lopez ⁴
 Gainer R Jasa Andrade ⁵

CORRESPONDENCE

Juan Manuel González Mollo:
guaguegonzalez@gmail.com

Received: March 22, 2024
Accepted: November 12, 2024



Key words: Linear tomography, image quality, inferior alveolar canal.

1 Doctor en Odontología. Ayudante de la Subunidad de Imagenología, Facultad de Odontología, Universidad de la República.

2 Doctora en Odontología. Facultad de Odontología, Universidad de la República.

3 Doctora en Odontología. Especialista en Ortodoncia y Ortopedia Dento-maxilofacial. Asistente de la Subunidad de Imagenología, Facultad de Odontología, Universidad de la República.

4 Doctor en Odontología. Asistente de la Subunidad de Imagenología, Facultad de Odontología, Universidad de la República.

5 Doctor en Ciencias Odontológicas. Master en Ciencias Odontológicas. Especialista en Imagenología Maxilofacial. Doctor en Odontología. Prof. Subunidad de Imagenología, Facultad de Odontología, Universidad de la República.

Resumen

Objetivo. Evaluar la influencia de la corriente y el voltaje del tubo de rayos x en la localización del conducto alveolar, por medio de la tomografía lineal. **Material y Métodos.** La muestra estuvo constituida por 24 hemimandíbulas que fueron escaneadas por un equipo de tomografía lineal utilizando diferentes combinaciones de Kv y mA. Las imágenes obtenidas fueron procesadas mediante el software ImagJ, obteniendo cortes coronales de las mismas, para luego ser observadas por cinco observadores. La precisión diagnóstica fue comparada mediante el área bajo la curva (Az) a través las curvas ROC (receiver operating characteristic curve), usando el software ROCKIT 1.1B. El índice Kappa intra e inter observador fue de 0.79 y 0.71 respectivamente. **Resultados.** Utilizando valores bajos de Kv (60 Kv) se lograron mayores Az (0.912). Cuando se varió el mA, el Az de mayor valor fue para 2 mA (0.911). **Conclusión.** Se recomienda utilizar valores bajos de corriente y voltaje del tubo de RX.

Palabras clave: Tomografía lineal. Calidad de imagen. Conducto alveolar inferior

Resumo

Objetivo. Avaliar a influência da corrente e da voltagem do tubo de raios X na localização do ducto alveolar por meio da tomografia linear. **Material e Métodos.** A amostra foi composta por 24 hemi-mandíbulas que foram escaneadas em equipamento de tomografia linear utilizando diferentes combinações de Kv e mA. As imagens obtidas foram processadas pelo software ImagJ, obtendo-se cortes coronais das imagens, que foram então observadas por cinco observadores. A acurácia diagnóstica foi comparada pela área sob a curva (Az) através da curva característica de operação do receptor (ROC) utilizando o software ROCKIT 1.1B. O índice Kappa intra e inter-observador foi de 0,79 e 0,71, respectivamente. **Resultados.** Utilizando valores mais baixos de Kv (60 Kv), obteve-se um Az mais elevado (0,912). Quando o mA foi variado, o valor mais elevado de Az foi para 2 mA (0,911). **Conclusão.** Recomenda-se a utilização de valores baixos de corrente e tensão do tubo de RX.

Palavras-chave: Tomografia linear. Qualidade de imagem. Ducto alveolar inferior

Introduction

Among the most frequent surgical procedures performed in the posterior region of the mandibular body are implant placement and third molar extraction. Both surgeries carry the risk of damaging the vasculonervous bundle, potentially leading to intraoperative and post-operative complications, such as hemorrhages and temporary or even permanent paresthesia⁽¹⁾. For this reason, it is essential to determine the exact location of the inferior alveolar canal (IAC) prior to surgery to prevent such injuries. Consequently, preoperative imaging studies play a critical role in assessing the location and course of the IAC to ensure the safety of both the patient and the professional during surgical procedures⁽²⁾.

The IAC begins behind and slightly below the lingula of the mandible, running obliquely downward and forward, usually reaching the second premolar. At this point, it divides into two branches: an external branch that emerges through the mental foramen, and an internal branch—the incisive canal—which ends below the antero-inferior incisors⁽³⁾.

Panoramic radiography, Computed Tomography, and

Linear Tomography are the main techniques used in preoperative imaging studies of the IAC⁽⁴⁾.

Panoramic radiography is the most widely used technique before mandibular bone surgery. However, because it provides a two-dimensional image, determining the exact location of the IAC can be challenging⁽⁴⁾.

Tomographies are the ideal method to determine the exact location of the IAC, as they provide its three-dimensional information. In the sagittal section, the IAC appears as a hypodense image bordered or surrounded by two hyperdense lines, while in the coronal section, it is enclosed in a circle by a hyperdense line⁽⁵⁾. Cone beam computed tomography (CBCT), in particular, is the first-choice method for studying the location of the inferior alveolar canal⁽⁶⁾. However, due to the high cost of CBCT equipment and the availability of panoramic devices that incorporate the linear tomography technique, the utility of linear tomography for locating the IAC is evaluated. This technique, originally called pantomography, was developed by Yrjö Paatero in 1949. It produces clear images of a curved layer of the subject on a

receptor by rotating the receptor and the x-ray tube in opposite directions. It was initially marketed under the name Panorex⁽⁷⁾.

Linear tomography (LT) provides information on the three spatial planes of the region of interest. It is more accessible and uses lower radiation doses compared to CBCT⁽⁸⁾. Additionally, LT is performed using panoramic x-ray equipment with an added LT function, making it a low-cost imaging study. LT is recommended for preoperative evaluations of single implants or segments with fewer than four implants, providing relevant information for assessing the bone structure of the jaws in three spatial planes. Thus, LT delivers an acceptable diagnostic image of the alveolar bone while maintaining low radiation doses⁽⁹⁾, in accordance with ALADA principles ("as low as diagnostically acceptable")⁽¹⁰⁻¹¹⁾.

Furthermore, it is not only important to understand the different imaging methods for locating the inferior alveolar canal, but also to recognize how various exposure factors, such as the voltage (kV) and current (mA) of the x-ray tube, affect the quality of the obtained image. Additionally, and especially relevant today, these exposure factors (mA and kV) have a significant impact on the radiation doses used.

Studies have confirmed the influence of radiation dose on diagnostic accuracy, showing that increasing the x-ray tube current improves the visibility of the inferior alveolar canal⁽¹²⁻¹³⁾. Image quality has also been found to improve with higher x-ray tube voltage. However, increasing the x-ray tube current and voltage leads to higher x-ray doses used. Therefore, it is important to study how the combination of these exposure factors affects the visibility of the inferior alveolar canal in linear tomography to best comply with the ALADA principle⁽¹⁴⁾.

Materials and Methods

SAMPLE

The sample used in this study consisted of 24 dry hemimandibles with edentulous ridges distal to the mental foramen, sourced from the Department of Radiology, Faculty of Dentistry, University of the Republic, Uruguay. The use of these mandibles and the research project were approved by the Ethics Committee of the Faculty of Dentistry (file number 091900-000018-23).

The entire length of the IAC was divided into three sections of equal length for each hemimandible (**Figure 1**). These sections were marked with gutta-percha, from the posterior margin of the mental foramen to the anterior margin of the mandibular foramen (spaces 1–4). For this study, mark 2 (the region of the first molar) was used for observation, as it is the most common site for implant placement.

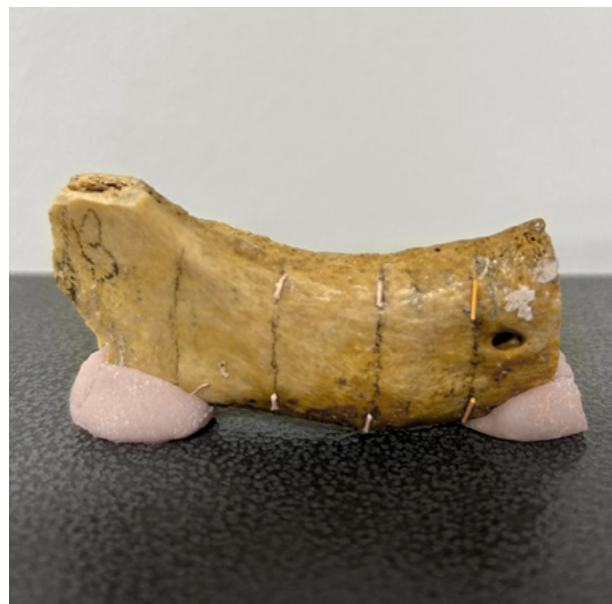

Figure 1. Hemimandible with gutta-percha marker in the study interval.

IMAGE ACQUISITION

Before scanning the tomographies, each hemimandible was secured inside a container (18 cm in diameter and 7 cm in height) with the basal edge parallel to the floor. The container was filled with water to simulate soft tissue radiation absorption⁽¹⁵⁾. The width and height of the container exceeded the field of view (**Figure 2**).




Figure 2. Hemimandible positioned for scanning.

Images of each hemiarch were acquired using linear tomography with panoramic equipment (Planmeca Pro max SD S3, Helsinki, Finland) (**Figure 3**). Prior to the first image acquisition, an orthodontic wire was placed inside the inferior alveolar canal of each hemimandible to mark the course of the IAC and obtain the gold standard. The exposure parameters for this first image were 66 kV, 2.5 mA, and an exposure time of 11.5 seconds (**Table 1**).

TABLE 1. Parameters used to obtain the Gold Standard.

GOLD STANDARD PARAMETERS

Exposure Parameters	Value
Tube Voltage (kV)	66
Tube Current (mA)	2.5
Scanning Time	11.5 s

Once the first tomography was performed, the wire was carefully removed from the mandibular bone, ensuring the sample remained stationary. Subsequent tomographies were performed using different combinations of kV and mA, as follows:

Stage 1: Using nearly identical radiation doses (DAP 230) to assess the effect of x-ray tube voltage (kV) on the location of the IAC: 60 kV/14 mA, 70 kV/10 mA, and 78 kV/8 mA (**Table 2**).

TABLE 2. kV and mA variations in Stage 1

STAGE 1: RADIATION DOSE 230

kV Variation	mA Variation
60	14
70	10
78	8

Stage 2: Using the same x-ray tube voltage (70 kV) and varying the mA, the following mA combinations (2 mA, 5 mA, 10 mA, 14 mA) were tested to evaluate the effects of the x-ray tube current on the localization of the IAC. Therefore, each hemimandible was scanned 8 times, resulting in a total of 192 images (**Table 3**).

TABLE 3. Variations of the x-ray tube mA in stage 2

STAGE 2: SAME TUBE VOLTAGE

Tube voltage kV	mA variation
70	2
70	5
70	10

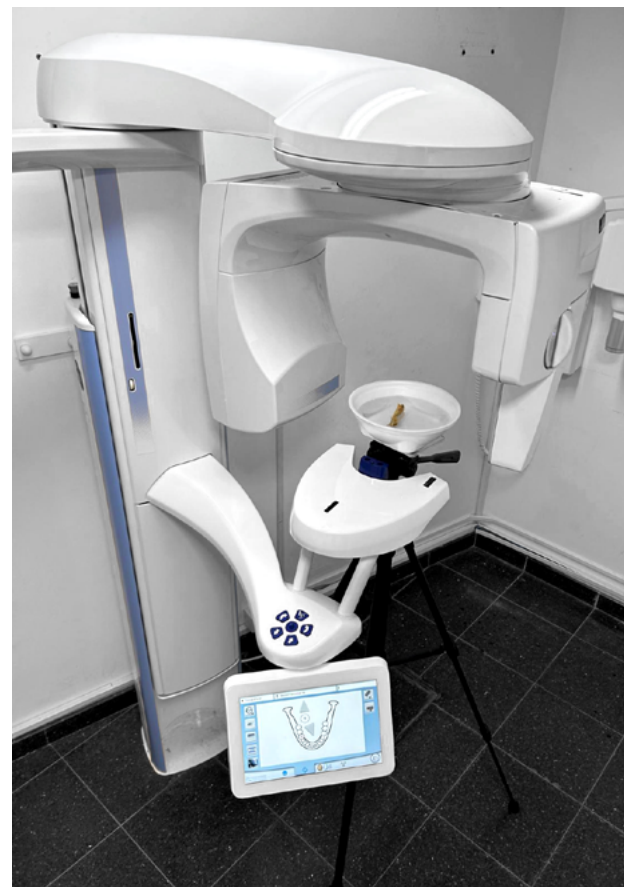

Figure 3. Scanning of the hemimandibles

PREPARATION OF THE IMAGES FOR OBSERVATION

The images obtained were imported in JPEG format for processing using ImageJ software (National Institutes of Health, Bethesda, MD) for observation.

In the coronal sections, the region of interest for observation was obtained by cropping two 1x1 cm squares, one showing the IAC and the other without it. (**Figura 4**).

Coronal section of the hemimandible

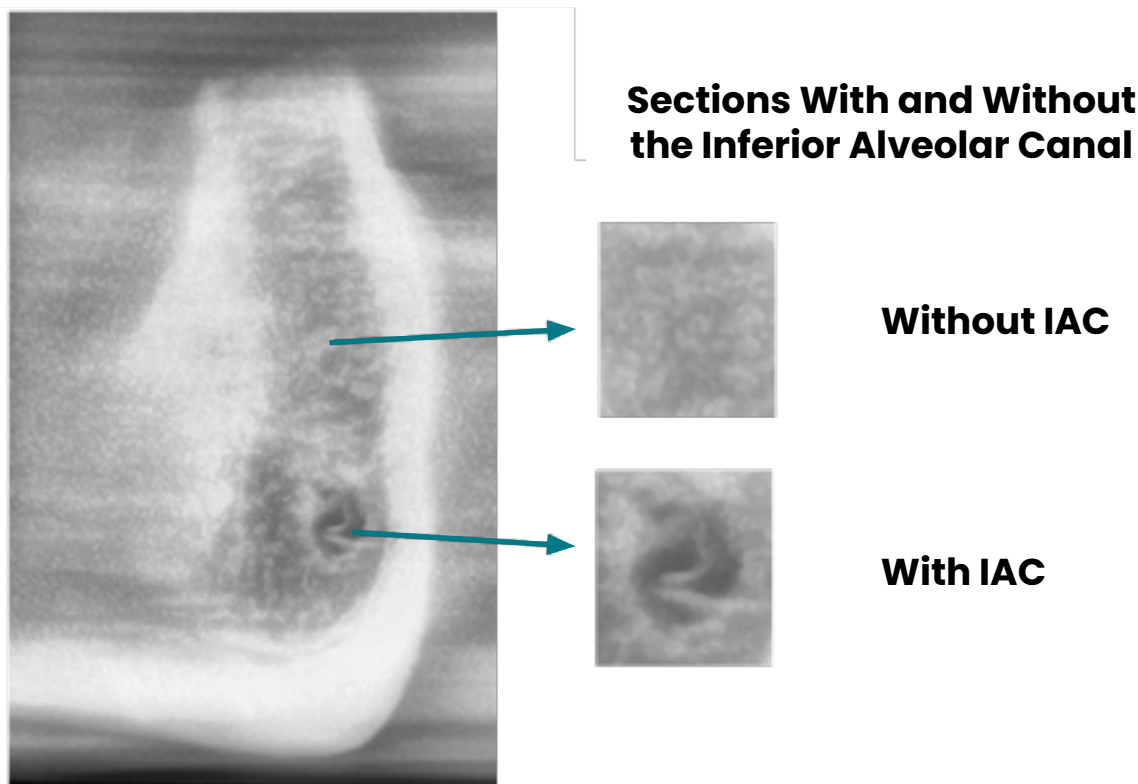


Figure 4. Cropped section of the region of interest. IAC (Inferior Alveolar Canal).

Then, the cropped images with and without the IAC were randomly stored on a computer to be viewed by 5 expert observers in a dimly lit room. A total of 384 images were analyzed by each observer. Each image was assigned a value from 1 to 5, based on the presence or absence of the IAC, as follows: 1. "Definitely present" 2. "Suspected to be present" 3. "Don't know" 4. "Suspected to be absent" 5. "Definitely not present" This methodology has already been applied in previous studies ^(16,17) and is based on the work of Hanley JA ⁽¹⁸⁾. The observations were conducted twice by each observer, with a 15-day interval between the first and second observation.

STATISTICAL STUDY

Intra-observer and inter-observer agreement was assessed using the kappa index, considering three categories: 1/2, 3, and 4/5. The agreement was classified as follows: values < 0.20 indicated poor agreement; 0.21 to 0.40, fair agreement; 0.41 to 0.60, moderate agreement; 0.61 to 0.80, good agreement; and 0.81 to 1.0, excellent agreement.

Diagnostic accuracy was evaluated using the area

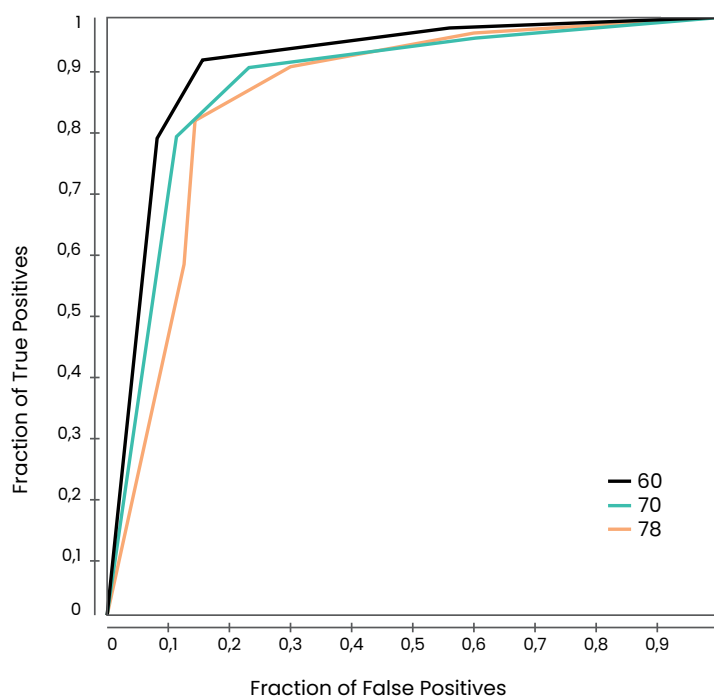
under the curve (Az) through receiver operating characteristic (ROC) analysis, using the ROCKIT 1.1B software (Charles E. Metz, University of Chicago, Chicago, IL, USA). The significance of differences between Az values was determined by the same software, based on confidence intervals.

Results

First, intra-observer and inter-observer agreement was calculated. Using the same data sets from Stages 1 and 2, the kappa indices were determined for this analysis. The intra-observer and inter-observer kappa indices were 0.79 and 0.71, respectively, demonstrating good agreement in both cases.

Figure 5 presents the kV values used in Stage 1: 60 / 70 / 78 kV. The corresponding Az values were 0.91, 0.85, and 0.86, respectively. Higher tube voltages resulted in lower Az values. A statistically significant difference was found between 60 kV and 78 kV ($p = 0.0176$); however, no significant differences were observed between 60 kV and 70 kV nor between 70 kV and 78 kV.

Receiver Operating Characteristic (ROC) Curves for Different Tube Voltages (60, 70, 78 kV)

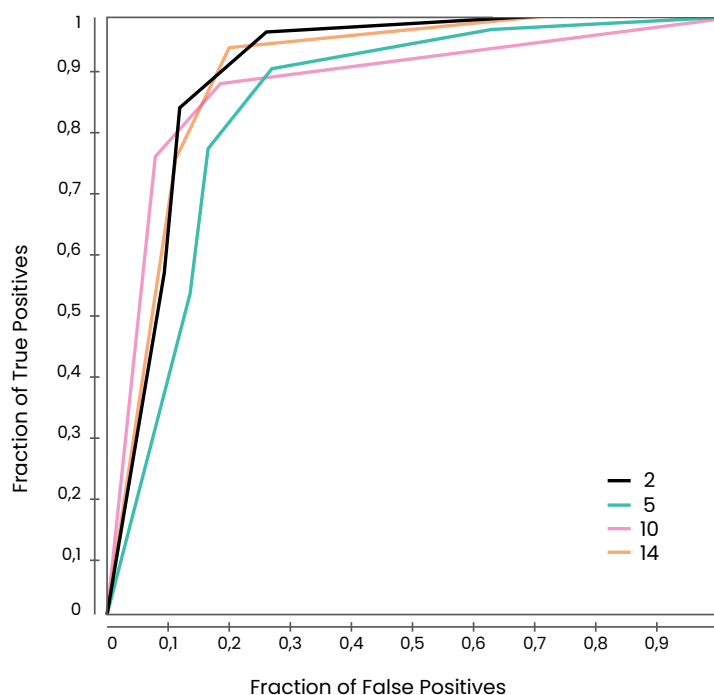


	1	2	3
Area under the curve	0,9192	0,885	0,8644
Estimation error	0,0189	0,0227	0,0242
Confidence interval (max)	0,9562	0,9295	0,9119
Confidence interval (min)	0,8822	0,8405	0,817

Figure 5:

Receiver operating characteristic (ROC) curve for different tube voltages (60, 70, 78 kV); with the table of values provided by the software.

Receiver Operating Characteristic (ROC) Curves for Different Tube Currents (2, 5, 10, 14 mA)



	1	2	3	4
Area under the curve	0,911	0,8555	0,8892	0,9056
Estimation error	0,0198	0,025	0,0224	0,0204
Confidence interval (max)	0,9499	0,9046	0,933	0,9455
Confidence interval (min)	0,8722	0,8064	0,8454	0,8656

Figure 6:

Receiver operating characteristic (ROC) curve for different tube currents (2, 5, 10, 14 mA) at a tube voltage of 70 kV; with the table of values provided by the software.

In **Figure 6**, the mA values used in Stage 2 (2, 5, 10, 14 mA) are compared. The Az values were 0.91, 0.85, 0.88, and 0.90, respectively. A significant difference was found between 2 mA and 5 mA ($p = 0.0172$), and between 14 mA and 5 mA ($p = 0.0106$). However, no significant difference was observed between 2 mA and 10 mA, nor between 2 mA and 14 mA, nor between 14 mA and 10 mA.

Discussion

This study aims to evaluate the influence of the x-ray tube current (mA) and voltage (kV) on the localization of the inferior alveolar canal using linear tomography. Identifying the IAC is crucial, as it contains a neurovascular bundle that can be lacerated during surgical procedures, potentially causing damage that may even be permanent. One major advantage of linear tomography over CBCT is the reduction in patient radiation dose, and even with lower radiation doses, it still provides high diagnostic value⁽⁹⁾.

The results in **Figure 1** show that the highest Az value corresponds to 60 kV, while the lowest corresponds to 78 kV. Therefore, better-quality images are obtained with lower kV values.

Regarding the mA values used, **Figure 2** shows that the 2 mA parameter has the highest Az value, followed by 14 mA, with no significant difference between them. However, a significant difference is observed when comparing 2 mA and 5 mA, as well as between 14 mA and 5 mA. Thus, using low mA values produces images with very good diagnostic quality while minimizing radiation doses.

These findings support the benefits of linear tomography (LT) as a viable alternative for preoperative studies, as it reduces radiation exposure while maintaining acceptable diagnostic quality. Unlike CBCT, LT allows precise control over exposure parameters, optimizing image quality while complying with the ALADA ("as low as diagnostically acceptable") principle. In addition, LT is more accessible and cost-effective, making it ideal for procedures in specific areas, such as the localization of the inferior alveolar canal in preoperative studies for single implant placement, without the need for the high radiation doses typical of CBCT⁽²⁰⁾.

Lindh et al.⁽¹⁸⁾ studied the most suitable radiographic method for visualizing the inferior alveolar canal. The radiographic techniques analyzed included periapical radiography, panoramic radiography, hypocycloidal tomography, spiral tomography, and computed tomography. Their research concluded that computed tomography is the best method for locating the inferior alveolar canal, as it not only provides a three-dimensional reconstruction of the mandible and the canal but also

offers better visualization. However, this comes at the cost of higher exposure parameters for the patient. Our study demonstrated that linear tomography not only produces high-value diagnostic images with good visualization of the inferior alveolar canal but also operates with lower exposure parameters and reduced costs for the patient. These advantages make linear tomography a preferable alternative to computed tomography.

Pauwels et al.⁽¹²⁾ used a combination of tube currents (1–8 mA) and voltages (60 kV, 70 kV, 80 kV, and 90 kV) and found an increase in the contrast-to-noise ratio at the highest tube voltage (90 kV) when the radiation dose was kept constant. Another study by Pauwels et al.⁽²¹⁾, which analyzed bone structure using the same radiation dose, showed that the contrast-to-noise ratio with the highest tube voltage protocol (90 kV) was significantly different from that obtained at lower tube voltage settings. Our study found that using lower kV values (60 kV) resulted in higher Az values (0.912), with a significant difference ($p = 0.0176$) between 60 kV and 78 kV, considering the confidence interval. When varying the mA, the highest Az value was obtained at 2 mA (0.911). However, there was a significant difference between 2 mA and 5 mA ($p = 0.0172$) and between 14 mA and 5 mA ($p = 0.0106$), but no significant difference between 2 mA and 10 mA, 2 mA and 14 mA, nor 14 mA and 10 mA.

Panmekiate et al.⁽²²⁾ acquired 160 CBCT datasets using eight different combinations of four tube voltage levels (60 kV, 80 kV, 100 kV, and 120 kV), two tube current levels (10 mA and 15 mA), and a scan time of 14 s. They concluded that low x-ray tube current values increased image noise, leading to the non-visualization of the IAC. Our study showed that although both 2 mA and 14 mA values produce images of high diagnostic value, there is no significant difference between them. This allows for a reduction in tube current during linear tomography, thereby lowering radiation doses.

A study by Svenson et al.⁽¹³⁾ concluded that variations in diagnostic accuracy depend on radiation dose, while the effect of x-ray tube voltage is practically negligible. In contrast, our study found that voltage variation significantly affects both image quality and radiation dose. Therefore, this work demonstrates that linear tomography enables the acquisition of high-value diagnostic images at tube voltages below 60 kV while achieving low radiation doses.

According to Neves et al.⁽¹⁴⁾, who acquired images with a sweep time of 10.8 s at 60 kV using seven different tube current combinations (2 mA, 4 mA, 6.3 mA, 8 mA, 10 mA, 12 mA, and 15 mA), and Jasa et al.⁽¹⁶⁾, who acquired images using different tube currents (2 mA, 5 mA, 10 mA, and 15 mA), image quality increased proportionally with higher mA values. However, our study

found that x-ray tube current variation did not result in a significant difference in IAC localization between 2 mA and 14 mA, as both had nearly identical Az values. A significant difference was observed, however, when

comparing 2 mA and 5 mA, as well as 5 mA and 14 mA. Lower tube current values are always beneficial for the patient, as they reduce radiation dose.

Conclusions

Linear tomography should be considered as a preoperative study option for locating the inferior alveolar canal, offering advantages over CBCT in terms of accessibility, lower radiation dose, and reduced cost. For inferior alveolar canal localization using linear tomography, low x-ray tube voltage values are recommended, as they yield better results than higher values, with significant differences observed between 60 kV and 78 kV. Regarding tube current, low values are advisable, as no significant difference was found between the lowest and highest values (2 mA and 14 mA), resulting in a lower radiation dose for the patient.

REFERENCES

1. Muñoz G, Dias FJ, Weber B, Betancourt P, Borie E. Anatomic Relationships of Mandibular Canal. A Cone Beam CT Study. *Int J Morphol*. 2017;35(4):1243–8. Disponible en: https://www.scielo.cl/scielo.php?pid=S0717-95022017000401243&script=sci_abstract
2. Domínguez Mejía J, Ruge Jiménez O, Aguilar Méndez G, Ñañez López Ó, Oliveros Torres G. Análisis de la posición y trayectoria del conducto alveolar inferior (CAI) en tomografía volumétrica computarizada (TC Cone Beam -TCCB). *Rev Fac Odontol Univ Antioq* 2010 Dec;22(1): 12-22. Disponible en: http://www.scielo.org.co/scielo.php?script=sci_arttext&pid=S0121-246X2010000200003
3. Canelo Martínez M. Uso de la tomografía computarizada de haz cónico en la detección de variantes anatómicas del conducto dentario inferior. Santo Domingo:Universidad Iberoamericana (UNIBE); 2021. Available at: <https://repositorio.unibe.edu.do/jspui/handle/123456789/771>
4. Beltrán Silva JA, Abanto Silva LE, Meneses López A. Disposición del conducto dentario inferior en el cuerpo mandibular: Estudio anatómico y tomográfico. *Acta odontol. venez.* 2007 Sep;45(3): 421-425. Disponible en: http://ve.scielo.org/scielo.php?script=sci_arttext&pid=S0001-63652007000300018
5. Kamrun N, Tetsumura A, Nomura Y, Yamaguchi S, Baba O, Nakamura S, et al. Visualization of the superior and inferior borders of the mandibular canal: a comparative study using digital panoramic radiographs and cross-sectional computed tomography images. *Oral Surg Oral Med Oral Pathol Oral Radiol* 2013; 115: 550–7. Available at: <https://pubmed.ncbi.nlm.nih.gov/23522648/>
6. Solis Vargas LD. Ortopantomografía (OPG) vs. Tomografía Computada (CT) en Imágenes Odontológicas Dentales. *Revista Ciencia y Salud Integrando Conocimientos*. 2023;7(1):43–58. Disponible en: <https://revistacienciaysalud.ac.cr/ojs/index.php/cienciaysalud/article/view/576>
7. Buzzi A.E., Suárez M.V. Linear Tomography: Birth, glory and decline of a method. *Rev. Argent. Radiol.* 2013; 77(3):236-244.
8. Flores Choquehuanca D, Moya Chávez LA. Tomografía Odontológica. *Rev. Act. Clin. Med.* 2013 Set. Disponible en: http://www.revistasbolivianas.ciencia.bo/scielo.php?script=sci_arttext&pid=S2304-37682013001100008&lng=pt&nr-m=iso
9. Beltrán Silva JA, Meneses López A, Ventura Ponce HR. Tomografía espiral convencional para implantes dentales: grado de magnificación. *Rev Estomatol Hered.* 2014;13(2–1). Disponible en: <https://revistas.upch.edu.pe/index.php/REH/article/view/2048>
10. Jaju PP, Jaju SP. Cone-beam computed tomography: Time to move from ALARA to ALADA. *Imaging Sci Dent* 2015. Available at: <https://pubmed.ncbi.nlm.nih.gov/26730375/>
11. Widmann G, Schönthaler H, Tartarotti A, Degenhart G, Hörmann R, Feuchtner G, et al. As low as diagnostically acceptable dose imaging in maxillofacial trauma: a reference quality approach. *Dentomaxillofac Radiol* 2023. Available at: <https://pubmed.ncbi.nlm.nih.gov/36688730/>
12. Pauwels R, Silkosessak O, Jacobs R, Bogaerts R, Bosmans H, Panmekiate S. A pragmatic approach to determine the optimal Kv p in cone beam CT: balancing contrast-to-noise ratio and radiation dose. *Dentomaxillofac Radiol* 2014; 43: 20140059. Available at: <https://doi.org/10.1259/dmfr.20140059>
13. Svenson B, Welander U, Anneroth G, Soderfeldt B. Exposure parameters and their effects on diagnostic accuracy. *Oral Surg Oral Med Oral Pathol* 1994; 78: 544–50. Available at: <https://pubmed.ncbi.nlm.nih.gov/7800386/>

14. Neves FS, de Camargo T, de Azevedo Vaz SL, Campos PS, Boscolo FN. Influence of cone-beam computed tomography milliamperage settings on image quality of the mandibular third molar region. *Oral Radiol* 2014; 30: 27–31. Available at: <https://pubmed.ncbi.nlm.nih.gov/25265127/>
15. Oliveira ML, Freitas DQ, Ambrosano GM, Haiter-Neto F. Influence of exposure factors on the variability of CBCT voxel values: a phantom study. *Dentomaxillofac Radiol* 2014; 43: 20140128. doi: <https://doi.org/10.1259/dmfr.20140128>
16. Jasa GR, Shimizu M, Okamura K, Tokumori K, Takeshita Y, Weerawanich W, et al. Effects of exposure parameters and slice thickness on detecting clear and unclear mandibular canals using cone beam CT. *Dentomaxillofac Radiol* 2017. Available at: <https://www.ncbi.nlm.nih.gov/pmc/articles/PMC5595001/>
17. Shimizu M, Okamura K, Kise Y, Takeshita Y, Furuhashi H, Weerawanich W, Moriyama M, Ohyama Y, Furukawa S, Nakamura S and Yoshiura S. Effectiveness of imaging modalities for screening IgG4-related dacryoadenitis and sialadenitis (Mikulicz's disease) and for differentiating it from Sjögren's syndrome (SS), with an emphasis on sonography. *Arthritis Res Ther* 2015;17(1):223. Disponible en: <https://www.ncbi.nlm.nih.gov/pmc/articles/PMC4546818/>
18. Hanley JA. Receiver operating characteristic (ROC) methodology: the state of the art. *Crit Rev Diagn Imaging*. 1989;29(3):307-35. Available at: <https://pubmed.ncbi.nlm.nih.gov/2667567/>
19. Lindh C, Petersson A, Klinge B. Visualisation of the mandibular canal by different radiographic techniques. *Clin Oral Implants Res*. 1992;3(2):90–7. Available at: <http://dx.doi.org/10.1034/j.1600-0501.1992.030207>.
20. Ludlow JB, Timothy R, Walker C, Hunter R, Benavides E, Samuelson DB, et al. Dosis efectiva de CBCT dental: un metaanálisis de datos publicados y datos adicionales para nueve unidades de CBCT. *Dentomaxillofac Radiol* [Internet]. 2015;44(1):20140197. Available at: <http://dx.doi.org/10.1259/dmfr.20140197>
21. Pauwels R, Araki K, Siewerdsen JH, Thongvigitmanee SS. Technical aspects of dental CBCT: state of the art. *Dentomaxillofac Radiol* 2015; 44: 20140224. Available at: <https://doi.org/10.1259/dmfr.20140224>
22. Panmekiate S, Apinhasmit W, Peterson A. Effect of electric potential and current on mandibular linear measurements in conebeam CT. *Dentomaxillofac Radiol* 2012; 41: 578–82. Available at: <https://doi.org/10.1259/dmfr/51664704>.

Data Availability

The entire dataset supporting the results of this study has been published in the article itself.

Conflict of Interest Statement

The authors declare that there are no conflicts of interest.

Ethics Committee

The research protocol was approved by the Ethics Committee of the Faculty of Dentistry, University of the Republic, on September 14, 2023

Funding Source

This research was conducted in the radiology laboratory using dry hemimandibles from the Imaging Department of the Faculty of Dentistry, UDELAR, with panoramic equipment (Planmeca ProMax SD S3, Helsinki, Finland). No funding was required, as all materials are available at the Imaging Department. It was carried out as part of the Final Project for the “Doctor of Dentistry” degree.

Authorship Contribution and Collaboration Statement

NAME AND LAST NAME	ACADEMIC COLLABORATION													
	1	2	3	4	5	6	7	8	9	10	11	12	13	14
Juan Manuel González Mollo			x	x	x	x	x			x				x
Carolina Riera Laiño				x	x									
Rocio Mott Gutierrez					x									
Flavio Echeverria Lopez					x									
Gainer R Jasa Andrade	x		x	x		x				x			x	

- | | |
|-------------------------------|--|
| 1. Project Administration | 8. Methodology |
| 2. Funding Acquisition | 9. Resources |
| 3. Formal Analysis | 10. Writing-Original Draft Preparation |
| 4. Conceptualization | 11. Software |
| 5. Data Curation | 12. Supervision |
| 6. Writing - Review & Editing | 13. Validation |
| 7. Research | 14. Visualization |

Acceptance Note:

This article was approved by the journal editor MSc. Dra. Natalia Tancredi